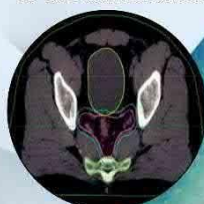


2^{ÈME} JOURNEE SCIENTIFIQUE DU SERVICE RADIOTHERAPIE CARCINOLOGIQUE DE SOUSSE

20 Avril 2024

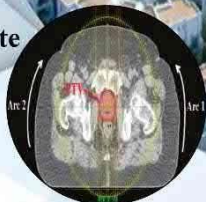**Cancer du Rectum
et du canal anal**



**Aspects médico-légaux
en Radiothérapie**



**Atelier :
Cancer de la Prostate**



2nd Scientific Day of the Cancer Radiotherapy Department, Farhet Hached University Hospital, Sousse, Tunisia, 20 April 2024

Conferences

1. Radiotherapy of rectal cancer : which neoadjuvant treatment for which patient ?

Vendrely V

Department of Radiation Oncology, Centre Hospitalier Universitaire de Bordeaux, Bordeaux, France; BoRdeaux Institute of onCology (BRIC), UMR1312, Inserm, Université de Bordeaux, Bordeaux, France.

The standard treatment for locally advanced rectal cancer consisted of chemoradiotherapy (CRT) followed by radical surgery with total removal of the mesorectum (TME) and adjuvant chemotherapy depending on lymphnode status. This radiosurgical strategy has reduced local recurrence rates to less than 5% in expert centers, albeit at the cost of 20-30% morbidity and functional sequelae. Recently, the guidelines have changed with the early introduction of neoadjuvant chemotherapy, which recent trials have shown to be beneficial in terms of recurrence-free survival and metastasis-free survival. The Prodigy 23 French trial has demonstrated that induction chemotherapy by Folfirinox 6 cycles before CRT improved disease-free survival, metastasis-free survival and overall survival. Simultaneously, the RAPIDO trial has shown that short-course radiotherapy (SCRT : 25Gy/5 fractions) followed by consolidation chemotherapy by Folfax or Capox decreased Disease-related treatment failure and improved metastasis-free survival without any overall survival increase, but at the cost of higher local recurrence rate. Several hypotheses could explain this high recurrence risk such as the decreased radioequivalent dose level with SCRT, the higher dose per fraction or the 3D conformal technique. However, the long time between the end of SCRT and surgery could have been detrimental, resulting in increased fibrosis, higher blood loss during surgery and incomplete mesorectum specimen. Nevertheless, both trials confirm the benefit of placing chemotherapy in a neoadjuvant setting. This so-called total neoadjuvant treatment achieves good oncological outcomes but at the cost of significant morbidity and functional sequelae. De-escalation strategy are therefore investigated, questioning the place of radiotherapy after induction chemotherapy for tumors with wide circumferential margins. In addition, chemoradiotherapy can sterilize 15% of tumours, depending on the series, and up to 30% in the case of associated neoadjuvant chemotherapy, calling into question the usefulness of systematic radical surgery in good responders. Therefore rectal preservation strategies are increasingly debated for good responders. Current trials focus on treatment intensification whether by chemotherapy or by radiotherapy dose escalation with contact-therapy or brachytherapy. In such strategies, patient selection and response assessment are major issues.

2. Rectum Surgery After TNT Protocol ? What's the difference?

Elghali MA

General and Digestive Surgery Department, CHH Farhat Hached Sousse, Tunisia

The occurrence of fibrosis when there is a long delay between radiotherapy and surgery is a well-known phenomenon. This fibrosis certainly makes dissection more difficult. The delay is 8 weeks after radio-chemotherapy in conventional fractionation and 1 week after short protocol. In 2018, meta-analysis by Wu et al showed that an 8-week delay after short protocol was associated with better tumor responses and fewer postoperative complications. However, since the advent of the RAPIDO protocol, this delay has increased to almost 20 weeks. The initial results of the RAPIDO protocol did not report any additional difficulties with surgery 5 months after 5x5 radiotherapy. In 2020, Van der Valk's multicenter study showed that peri-operative bleeding was statistically higher in the RAPIDO group. This can only be explained by the difficulty of pelvic dissection due to the fibrosis and bleeding origin of the sacral veins. Two meta-analyses published in 2021 and 2022 in Oncologist and PLoS one, respectively collating 14 and 15 randomized studies comparing results after TNT vs. conventional protocol, concluded that the rate of local recurrence was higher in the TNT group, despite better systemic and local disease. Finally, a very recent meta-analysis published in 2024 in Annals of Surgery concluded that the rate of poor resection of the mesorectum was statistically higher in the TNT group. These results contribute to the direct or indirect conclusion that surgery after the RAPIDO protocol is more difficult because of pelvic fibrosis, and that this has an impact on carcinological results. In the near future, these results will certainly lead us to propose protocols where the radiotherapy-surgery interval is shortened to 8 weeks, with chemotherapy preceding radiotherapy or following surgery. In the meantime, it's important to remember that surgery for rectal cancer requires surgical expertise, and surgery after RAPIDO is even more laborious, requiring even more surgical expertise.

3. Current issues in radiotherapy for anal cancer

Vendrely V

Department of Radiation Oncology, Centre Hospitalier Universitaire de Bordeaux, Bordeaux, France; BoRdeaux Institute of onCology (BRIC), UMR1312, Inserm, Université de Bordeaux, Bordeaux, France.

Squamous cell carcinoma of the anus (SCCA) is a rare disease, but its annual incidence has increased in the recent decades due to the high prevalence of HPV infection. When localized, the standard treatment combines intensity-modulated radiotherapy (IMRT) and chemotherapy with 5-fluorouracil (or capecitabine) and mitomycin-C. While this therapeutic strategy provides good results for early-stage tumors (T1-T2, N0) with a 5-year survival rate of around 80% and very good local control, locally advanced tumors (T3-T4 or N+) still present a poor prognosis with 35% recurrence at local or distant sites. Therapeutic intensification trials with dose escalation or with (neo)adjuvant chemotherapy with CDDP-5FU have not proven any benefit, as have anti-EGF associated with radiotherapy. The challenge of treatment remains locoregional control while reducing toxicity and sequelae. Surgery is reserved for tumors with incomplete response or recurrence after chemoradiotherapy, and consists of abdominoperineal amputation. For metastatic or recurrent disease

after chemoradiotherapy or surgery, taxane based chemotherapy wether with Docetaxel, Cisplatin and 5FU (mDCF) or with Carboplatin and docetaxel, is recommended following the results of the Epitopes-HPV02 trial and Inter-AACT trial respectively. New approaches are investigated such as de-escalation or intensification trials according to tumor stage as well as the development of immunotherapies.

4. Medico-legal aspects of radiotherapy

Ben Dhiab M, Makni C

Department of Forensic Medicine, Farhat Hached University Hospital, Sousse, Tunisia

Radiotherapy is an essential component of cancer treatment, offering significant therapeutic benefits for many patients. However, there are several challenges that radiotherapy healthcare professionals face in their daily practice. This raises a range of important medico-legal issues that these healthcare professionals need to consider.

Our objectives were to expose and discuss the main medico-legal aspects related to the practice of radiotherapy and to promote responsible and ethical professional practices, with the aim of ensuring quality care and protecting the rights and well-being of patients.

Patient safety and well-being must always be our top priority. By integrating the principles of safety and quality into our practice, we can reduce the risk of medical errors and legal disputes. Informed consent is essential to ensure that patients fully understand the implications of their radiotherapy treatment. Healthcare professionals must provide clear, objective, and comprehensible information on treatment options, risks and benefits. Collegial decision-making must be favored to ensure the best care pathway for the patient. The development of guidelines and compliance with protocols are essential to ensure proper patient care, and to protect the healthcare professional in the event of a litigation or legal complaints. Ongoing training and professional development are also essential to keep abreast of the latest medical, regulatory and legal advances in the field of radiotherapy.

Radiation therapy professionals are required to maintain a high level of professional competence, effective communication with patients and strict adherence to treatment protocols and medical procedures. Medico-legal risks can only be reduced by ensuring diligent and legally compliant practice.

Oral presentations

1. Watch and Wait approach: the organ preservation strategy for lower rectal cancer

Ben Hassine H, Hadj Taieb A, Mazigh R, Ben Jabra S, Korbi I, Faouzi N

General Surgery Departement, CHU Fattouma Bourguiba

Introduction: Colorectal cancer is the second most common digestive cancer in Tunisia. The management of locally advanced lower rectal cancer mainly relies on neoadjuvant radiochemotherapy and total mesorectal excision. However, functional outcomes and post-resection quality of life remain suboptimal. The Watch and Wait approach offers a non-invasive alternative for organ preservation and reduction of operative morbidity.

Method and Materials: This retrospective unicentric descriptive study collected 15 cases of lower rectal cancer that achieved complete sterilization after neoadjuvant treatment between January 2006 and December 2020.

Results: The mean age was 53.13 years, with male predominance. Rectal bleeding was the main symptom. All patients underwent rectoscopy with biopsy, showing an ulcerative-proliferative process in 86.66% of cases, ranging in size between 2.5 and 4 cm, with an initial stage of T3. Histological examination revealed well-differentiated adenocarcinoma in 73.33% of cases. All patients received varied neoadjuvant treatment. Reevaluation was performed between 6 and 7 weeks, showing negative biopsies in 10 patients, fibrotic areas in 7, and a colloid response in 3. Radical surgery was performed in most patients after 7 to 9 weeks of neoadjuvant treatment, although 40% refused surgery. The average follow-up was 2.91 years, with two cases of locoregional recurrence detected after 1 and 2 years, treated surgically with chemotherapy. Two other cases that did not undergo surgery presented recurrence, one locoregional after 3 months and the other as hepatic metastases, treated with palliative chemotherapy.

Conclusion: The Watch & Wait approach requires a precise evaluation of benefits and risks focused on patient preferences to choose the appropriate treatment.

2. Patient information and consent in Radiotherapy: legal and ethical aspects

Kedhaouria N, Ben Abderrahim S, Mami Y, Turki E

Forensic Medicine Department, Ibn El Jazzar University Hospital, Kairouan, Tunisia

Introduction: Informed patient consent is a legal requirement for all medical treatment, particularly for patients undergoing radiotherapy. However, the information and consent of patients suffering from a pathology with a poor prognosis often raises numerous ethical and legal questions. We aimed to study the legal aspects of patient consent in the radiotherapy field and discuss the main ethical issues involved.

Methods: We reviewed the main Tunisian legal texts and ethical guidelines governing patient consent and information in radiotherapy.

Results: In Tunisia, information and consent are governed by the patient Charter and Decree no. 81-1634 of November 30, 1981, on the general internal regulations of hospitals. The patient charter clearly defines the doctor's duty to inform the patient about the diagnosis of the disease, the purpose and risks of the proposed investigations, the expected benefits and possible side effects of treatment, and the monitoring procedures. Informed consent requires that information should be clear, fair, and appropriate. This includes prior information for radiotherapy sessions. To provide written proof of the information provided by the doctor, informed consent forms have been introduced on the initiative of certain radiotherapy boards. Thus, it is now common practice to find in medical files documents signed by the patient, attesting to his or her full information and the informed nature of his or her choice. However, these forms are only a complement to oral information and are not mandatory. Yet can we speak of free consent in the case of patients distressed by their illnesses, sometimes forced to opt for aggressive treatment? Should we respect the autonomy of a patient at the end of life who takes refuge in social and relational denial? Should we respect the refusal of care by a patient already weakened by cancer?

Conclusion: Consent to care for cancer patients undergoing radiotherapy is a fundamental right of the patient and a duty of the doctor. Legal and ethical principles must be respected, especially in the case of cancer patients who may be at the end of their lives.

3. Sexual Health and self-esteem in Prostate cancer

Mokrani C¹, Noubbigh G², Ben Zid K¹, Attia N¹, Lajnef I³, Ben Nasr S³, Zarra S¹, Nasr C¹

1) Radiation oncology department, Salah Azaiz Institute, Tunisia

2) *The Military Hospital of Tunis, Tunisia*

3) *Medical oncology department, The Military Hospital of Tunis, Tunisia*

Introduction: The improvement in medical techniques has modified the practice of care in oncology. Nowadays, studies are increasingly focusing on various aspects of patients' well-being as primary outcomes. Patient's sexual health after prostate cancer can be affected in many ways. The main of this study is to assess sexual well-being and self-esteem among patients who undergone prostate cancer treatment.

Methods: Survey among 30 patients treated for non-metastatic prostate cancer in the past ten years at the Salah Azaiz Institute. Sexual health and self-esteem were assessed using the Relationship and Sexuality Scale (RSS) and the Rosenberg Self-Esteem Scale.

Results: In our study, medium age at diagnosis was 69 years. All patients were married since the diagnosis and remain so. ISUP grade group 3 was the most prevalent (46.7%) followed by grade 1 (27%). The involvement of seminal vesicles was found in 33%, as well as the involvement of both prostatic lobes. The predominant treatment approach involved a combination of radiotherapy and long-term hormone therapy. Only 6 patients were treated by radical prostatectomy and received adjuvant irradiation. With a medium follow up of 5.6 years, all patients expressed an interest in their sexuality, yet declared that none of the healthcare staff showed interest in their sexual issues. The majority mentioned that their sexual life was negatively affected by treatment modalities and not by the disease itself, regardless of the approach. 46% of patients are having sexual relations approximately once every two weeks. Half of patients reported that they were not informed about the potential side effects. Sixteen patients regretted their choice of treatment (54%). The majority showed high self-esteem, regardless of their age and the frequency of their sexual relations.

Conclusion: Recognizing sexual health concerns is essential to provide comprehensive care for prostate cancer survivors. Patients should have access to support and treatment option that can help them improve and accept their sexual life after remission.

4. Assessment of Quality of Life in Cancer Patients Undergoing Curative Radiotherapy: A single institutional Tunisian experience

Tbessi S, Meddeb I, Yazid D, Ben Ali B, Chamsi A, Abdeltif I, Bettaieb O, Kenoun S, Bouzid N, Tebra S

Radiotherapy Department, Farhat Hached Hospital, Sousse, Tunisia

Introduction: Cancer is often perceived as an image of death and catastrophe, thus having a significant impact on the quality of life of patients undergoing various treatments for cancer. Quality of life (QOL) is a crucial parameter to be evaluated as well as survival outcomes.

Objective: In this study, we proceeded to evaluate the QoL among 30 cancer patients undergoing curative radiotherapy (RT) using the EORTC: Quality of Life Questionnaire Core 30 (QLQ C-30).

Methods: We prospectively evaluated the quality of life of cancer patients undergoing curative RT at the radiotherapy department of Farhat Hached Hospital. The QLQ C-30 questionnaire was used including multiple domains assessing physical, role, emotional, cognitive and social functioning.

Results: A total of 30 cancer patients undergoing curative RT were included in the study, the patients undergoing palliative treatment were excluded. The mean age was 55 years old [19-76]. The sex ratio was 1.7. The average of functional scales was 70%. The Emotional functioning scores are the most who demonstrated a decline during treatment with an average of 55%. Conversely, cognitive scales demonstrated the highest preservation, with a score of 78%. Symptom scales, encompassing fatigue and pain, were rated equally at 33.3%. Financial aspects were rated at 37%. Overall, patients rated their global health at an average of 60%.

Conclusion: Despite the emotional toll of treatment, patients exhibited resilience, with overall global health rated at 60%. which is globally acceptable. Symptom management, financial concerns, and gender disparities were notable aspects affecting QoL. Tailored supportive interventions addressing these factors are important for optimizing QoL outcomes in cancer patients undergoing radiotherapy.

5. Comparative Analysis of GPA Score and Actual Survival in Patients Treated with Whole Brain Irradiation for Metastatic Cancer

Ben Ali B, Bettaieb O, Ghommidh A, Sghaier S, Meddeb I, Tbessi S, Belaajouza S, Bouzid N, Tebra Mrad S.

Radiotherapy Department, Farhat Hached hospital, Sousse, Tunisia.

Introduction: Whole brain irradiation (WBI) is a common palliative treatment modality for brain metastatic cancer, often guided by the graded prognostic assessment (GPA). However, little research has explored GPA-predicted versus actual survival alignment in this setting.

Objective: To compare GPA-predicted survival with actual survival in WBI-treated brain metastatic cancer patients.

Patients and Methods: A retrospective study at the Radiotherapy Department of Farhat Hached University Hospital involved WBI-treated patients between January-December 2023. Data included demographic details, GPA scores, and survival outcomes. Concordance was noted if actual survival met or exceeded predicted survival.

Results: Twenty-nine patients with median age 56.59 (33 - 83 years) were included. 14 patients were treated for metastatic lung cancer, 14 patients were treated for metastatic breast cancer and 1 patient was treated for metastatic rectal cancer. 28 patients received a dose of 20Gy in 5 fractions and one patient received 37.5Gy in 15 fractions. The median predicted survival according to GPA score was 12.68 months (3-25.3 months) while the median actual survival was 6.7 months (1 - 24 months). Results were concordant for 5 patients (17.24% of cases) with 4 patients among them exceeding the predicted survival. 3 patients (10.34%) are still alive but not yet reached the predicted value. The remaining 21 patients (72.41%) did not reach the predicted survival and therefore did not have concordance with their GPA score.

Conclusion: Significant discordance exists between GPA-predicted and actual survival in WBI-treated brain metastatic cancer patients. Optimal treatment strategies may be necessary to achieve predicted survival aligned with GPA scores.

Posters

1. Intra-operative factors predicting recurrence after curative resection for rectal cancer

Ben Latifa M^{1,2}, Harrabi F^{1,2}, Lagha S^{1,2}, Kenani N¹, Ben Mabrouk M^{1,2}, Ben Ali A^{1,2}

1) General Surgery Department, Sahloul University Hospital, Sousse, Tunisia

2) Faculty of Medicine of Sousse, University of Sousse, Sousse, Tunisia

Introduction : Recurrence after curative surgery is one of the major factors affecting the long-term survival. Several patient, tumor and treatment related prognostic factors are associated with the risk of recurrence. The recognition of these factors helps in the identification of high-risk patients who require close and more rigorous post-operative surveillance. The aim of this work is to identify intra-operative factors predicting recurrence after curative resection of rectal cancer.

Methods : We conducted a retrospective study that collected rectal adenocarcinoma treated between January 2000 and December 2018 at

Sahloul university hospital general surgery department. Survival data were studied by establishing survival curves according to the Kaplan-Meier method. The search for prognostic factors for survival was carried out in univariate then multivariate analysis.

Results : During the study period, we included 188 patients. Among the studied population, 43 patients had a loco-regional recurrence (23%). On univariate analysis : the emergency of the surgery and a distal resection margin < 2 cm were reported with significant statistical data as a risk factor for local recurrence of rectal cancer. On multivariate analysis : a distal resection margin < 2 cm was the only intra-operative independent Potential risk factor for local recurrence. In our study, neither the surgical approach, nor the experience of the surgeon were significantly associated with the risk of recurrence.

Conclusion : Local Recurrence is the most important oncologic outcome measure after rectal cancer surgery. This study emphasizes the importance of reviewing intra-operative factors to ensure that standardized processes and best practice are applied.

2. Potential risk pathological factors for local recurrence of rectal cancer

Ben Latifa M^{1,2}, Harrabi F^{1,2}, Said MA^{1,2}, Kermani I¹, Ben Mabrouk M^{1,2}, Ben Ali A^{1,2}

1) General Surgery Department, Sahloul University Hospital, Sousse, Tunisia

2) Faculty of Medicine of Sousse, University of Sousse, Sousse, Tunisia

Introduction : Up to a third of patients who have undergone surgery for rectal cancer with curative intent will have a recurrence of the disease. There have been multiple pathological prognostic factors identified for recurrence that seem to be important to recognize to establish a post operative treatment strategy. The aim of this work is to specify the potential risk pathological factors for local recurrence of rectal cancer.

Methods : We conducted a retrospective study that collected rectal adenocarcinomas treated between January 2000 and December 2018 at Sahloul university hospital general surgery department. Survival data were studied by establishing survival curves according to the Kaplan-Meier method. The search for prognostic factors for survival was carried out in univariate then multivariate analysis.

Results : During the study period, we included 188 patients. Among the studied population, 43 patients had a loco-regional recurrence (23%). On univariate analysis : parietal invasion pTNM T3-4, lymph node involvement, III-IV TNM stage, lymph node capsule effraction, perineural invasion and vascular embols were reported with significant statistical data as risk anatomopathological factor of local recurrence of rectal cancer. On multivariate analysis : lymph node involvement and perineural invasion were identified to be the independent Potential risk factors for local recurrence.

Conclusion : Local Recurrence is the most important oncologic outcome measure after rectal cancer surgery. High-risk tumour pathological features develop recommendations for clinical practice and were used to recommend adjuvant treatment.

3. Predictive factors for recurrence of colorectal cancer

Ben Hassine H, Hadj Taieb A, Ghali H, Jallali M, Korbi I, Faouzi N

General Surgery Department, CHU Fattouma Bourguiba

Introduction: Colorectal cancer represents 3.2% of all cancers in Tunisia, all locations combined. Recurrence after curative surgery is defined as a resumption of tumor progression within the limits of the operating field or at a distance. It represents an important step in the history of the disease by reducing the patient's life expectancy with a profound alteration in his quality of life.

Methodology: a multicentric retrospective study that collected adenocarcinomas of the left colon and rectum treated between January 2010 and December 2018 at Tunisian department Surgery.

Results: During the study period, we counted 1421 cases of colorectal cancer. These were 750 men and 671 women; the average age of our patients was 61.86 ± 13.7 years with extremes ranging from 18 to 97 years. The single-factor analytical study of the parameters influencing recurrence-free survival revealed 23 significant prognostic factors: Young age (p: 0.04), family history of colorectal cancer p=0.001, The Tumor location (middle and low rectum versus left colon and upper rectum) (p: 0.04); Tumor fixity (p: 0.027); Sphincter invasion (p: 0.001); invasion of peri rectal fat (p: 0.001); The stenotic nature of the tumor (p: 0.03); The ACE rate (p: 0.025); Adjuvant chemotherapy (p: 0.01); The surgical procedure (p: 0.025); A distal resection margin less than or equal to 2 cm (p: 0.02); Intraoperative transfusion (p: 0.061); The occurrence of intraoperative incidents (p: 0.007); Intraoperative tumor effraction p<0.01; Parietal invasion (p: 0.01); Invasion of neighboring organs (p: 0.014); Tumor perforation (p: 0.007); Lymph node involvement (p: 0.001); Capsule breaking (p: 0.001); . The presence of vascular emboli (p: 0.001); The presence of Nervous sheathing (p: 0.001); The tumor stage (p: 0.003) and The quality of excision (p: 0.003).

Conclusion: the prevention of local recurrences must go through An identification of groups at high risk of recurrence. Indeed, these patients must be subjected to very close clinical and paraclinical monitoring, especially during the first two years, in order to detect local recurrences as early as possible at a stage still accessible to curative surgery.

4. Surgical management of loco regional recurrence after curative surgery for rectal cancer

Ben Latifa M^{1,2}, Harrabi F^{1,2}, Bouazzi A^{1,2}, Ben Ali Az¹, Ben Mabrouk M^{1,2}, Ben Ali A^{1,2}

1) General surgery department, Sahloul university hospital, Sousse, Tunisia

2) Faculty of Medicine of Sousse, University of Sousse, Sousse, Tunisia

Introduction : Nowadays, the overall survival after curative surgery for rectal cancer has improved due to better knowledge of multimodal treatment. However, recurrence after curative treatment is still a controversial theme. In this study, we will discuss the surgical management of loco regional recurrence following curative treatment of rectal cancer.

Methods : We conducted a retrospective study that collected rectal adenocarcinomas treated between January 2000 and December 2018 at Sahloul university hospital general surgery department.

Results : During the study period, we included 188 patients. Among the studied population, 43 patients had an isolated loco-regional recurrence (23%). 27 patients were re-operated for their recurrence, 9 of whom had pre or post-re-intervention radiotherapy. The resection was qualified as R0 in 22 cases and The average survival was 19 months after re-intervention compared to a survival of 7 months if abstention.

Conclusion : Patients presenting with isolated loco-regional recurrence may be potentially curable by radical resection. It requires specialized input from multiple teams. The aims are to improve quality of life, prolong survival and provide cure wherever possible, while minimizing associated morbidity.

5. Waiting lists for radiotherapy in Tunisia: Ethical challenges and how to face them

Mani Y, Ben Abderrahim S, Kedhaouria N, Turki E

Department of Forensic Medicine, Ibn El Jazzar University Hospital, Kairouan, Tunisia

Introduction: These last decades have seen an elevation of cancer diagnosis and with it, more need for radiotherapy. With limited resources, a waiting list for patients undergoing radiotherapy constantly emerges for physicians. Many countries faced these challenges by creating programs and frameworks to organize the lists and implementing many strategies to shorten the waiting time but in Tunisia, no formulated solution has been developed yet. We aimed to discuss the ethical dilemmas when dealing with waiting lists for radiotherapy in Tunisia and explore strategies employed in other countries to address waiting list management and reduction.

Methods: We reviewed existing literature to examine the ethical concerns and strategies relevant to radiotherapy access in Tunisia, the usual waiting time, and how waiting lists are usually created.

Results: The main ethical dilemmas found were: decreased preventable patient survival rates, access disparities, and discriminatory behavior such as ageism. While other countries implemented strategies to face these challenges such as well-researched prioritization frameworks, expanding healthcare infrastructure, and training more medical personnel, existing literature suggests the absence of a well-defined framework for prioritizing patients on waiting lists in Tunisia and the lack of effort to reduce the waiting time.

Conclusion: The ethical challenges facing physicians and patients with radiotherapy waiting lists in Tunisia need immediate and thorough action and reports on the usual waiting time. Implementing prioritization frameworks nationwide is the only way to ensure equitable and timely access to radiotherapy for patients.

6. Radioprotection in Radiotherapy: legal and ethical aspects

Nadhem Kedhaouria, Sarra Ben Abderrahim, Yasmine Mani, Elyes Turki.

Department of Forensic Medicine, Ibn El Jazzar University Hospital, Kairouan, Tunisia

Introduction: Ionizing radiation is used in different medical fields. Responsibilities depend on whether we are interested in the radiation protection of workers, the public, the environment, and the patients. This topic raises numerous ethical and legal questions.

Aim: To study the legal aspects of radioprotection in the radiotherapy field and discuss the main ethical issues involved.

Methods: We reviewed the main Tunisian legal texts and ethical radioprotection guidelines.

Results: In Tunisia, radioprotection is governed by Law n° 81-51 of June 18, 1981, Law n° 81-100 of December 31, 1981, Decree n°82-1389, of October 27, 1982, on the organization and responsibilities of the CNRP, and Decree n° 86-433, of March 28, 1986, on protection against ionizing radiation. However, by focusing on technical and scientific achievements, the radioprotection framework seems not to benefit sufficiently from the ethical aspects that fields such as bioethics can bring. Today with this insufficiency, we find ourselves unfortunately facing important ethical issues such as the exposure of practitioners carrying out these radiological techniques or the lack of information about radiation risk for patients. There are three principles of radioprotection which are justification, optimization, and limitation. Indeed, these principles are linked to four main ethical criteria: beneficence/non-maleficence, prudence, justice, and dignity. The justification principle means that every decision that changes the exposure situation must do more good than harm. The principle of optimization means that all exposures should be kept as low as reasonably possible. The limitation principle states that individual exposures should not exceed recommended dose limits.

Conclusion: To assume their responsibility, all practitioners must benefit from technical training adapted to their medical acts as well as training in radioprotection. Legal and ethical principles must be respected, in order to prevent dramatic damage that may arise over years.

7. Curative reirradiation in a case of recurrent sino-nasal adenoid cystic carcinoma

Kaabia W, Mousli A, Ben Zid K, Yousfi A, Ghorbel A, Abidi R, Nasr C.

Radiation-Oncology department, Salah Azaiez Institute, Tunis, Tunisia

Introduction: Re-irradiation for local relapses of adenoid cystic carcinoma (ACC) of the head and neck is a challenging task. The aim of this study was to analyse the clinical and dosimetric parameters of such treatment through a case presentation.

Case report: We present the case of a 60-year-old man with ACC of the left ethmoidal sinus. After a large exenteration in 2006 with clear surgical margins, a local recurrence occurred one year later requiring 2D cobalt radiotherapy (64Gy, 2Gy/fraction). A second recurrence seven years later was treated by surgery without adjuvant therapy. Eighteen years after the initial diagnosis, an inoperable local recurrence was confirmed by biopsy, presenting as a large 85mm tumour invading the remaining ethmoidal cells, the left masticatory space and the left buccal space (rT4N0M0). Multidisciplinary team consultation led to a recommendation for re-irradiation. Treatment plan was done at a dose of 60Gy (2Gy/fraction) via two partial arcs using volumetric intensity modulated radiotherapy (VMAT). The decision was guided by an assessment for survival predictors, confirming that the patient met three criteria: absence of concurrent chemotherapy with initial radiotherapy, time to re-irradiation \geq 36 months and a prescribed dose at re-irradiation \geq 60Gy. Considering the long delay since the last irradiation, a dosimetric adjustment involving a 50% reduction in the original dose to the organs at risk (OAR) was applied. The coverage of the predicted target volume (PTV) was optimal (V95%=98%, D2%=105%). The dosimetric constraints for the organs at risk (OAR) were respected; in particular, the maximum doses for the brain stem (20.4Gy), chiasma (24.7Gy), left internal carotid artery (35.2Gy), and facial bones (63.8Gy). Being aware of the risk of carotid artery blow-out, radionecrosis, or radiomyelitis, our treatment plan met both the target volume objectives while protecting the noble OARs.

Conclusion: This case highlights the therapeutic and dosimetric challenges inherent in the management of sinonasal ACC. A multidisciplinary approach remains essential to optimise patient outcomes, and the decision to re-irradiate must be carefully evaluated taking into account patient-specific factors.

8. Subependymal giant cell astrocytomas (SEGAs): A case report

Mousli A, Daghfous Y, Yousfi A, Ben Zid K, Ghorbel A, Zarea S, Abidi R, Nasr C

Radiotherapy Department of Salah Azaiez Institute, Tunis, Tunisia

Introduction: Subependymal giant cell astrocytomas (SEGA) are benign supratentorial midline tumors arising from the wall of the lateral ventricle adjacent to the foramen of Monro. They are usually associated with tuberous sclerosis (TSC), but can also occur idiopathically. Although SEGAs have low proliferation potential, they often present with clinical signs of intracranial hypertension and can cause death.

Patient and observation: We report the case of a 33-year-old patient, without significant medical history, presenting symptoms of intracranial hypertension. MRI revealed an expansive lesion in the posterior fossa, with lobulated contours and without contrast enhancement, initially suggestive of an epidermoid cyst. The patient underwent surgery, resulting in a macroscopically complete resection, with histological examination confirming a grade I subependymal giant cell astrocytoma. Postoperatively, the patient remained asymptomatic except for residual right hemiparesis. Follow-up MRI, two years after surgery, revealed postoperative changes with significant posterior and medial cerebrosplinal fluid collection and recurrence of the expansive lesion in the posterior

fossa. The patient was referred for adjuvant radiotherapy. However, considering the low radiosensitivity of the tumor, based on the multidisciplinary decision of the tumor board and literature analysis, targeted therapy with mTOR inhibitors emerged as a potential alternative, especially considering its effectiveness in managing other TSC events.

Conclusion : Surgical resection remains the mainstay of treatment for SEGA. The advent of mTOR inhibitor therapy has significantly influenced therapeutic decision-making, particularly in TSC patients. Radiotherapy appears less effective due to lower sensitivity. SEGAs remain rare tumors requiring prospective studies and randomized trials to refine management strategies.

9. Challenges in treating a rare case of oral malignant melanoma

Mokrani C, Abidi R, Ben Zid K, Mousli A, Attia N, Yousfi A, Nasr C

Radiation Oncology Department, Salah Azaiz Institute, Tunisia

Introduction: Oral malignant melanoma is a very rare aggressive tumor occurring mainly in men. Its local malignancy makes the therapeutic journey very challenging. The standard of care typically involves surgery combined with adjuvant therapies including immune checkpoints and radiotherapy.

Materials et methods: We report the case of a 58-year-old woman with melanoma of the hard palate managed with palliative radiotherapy. This case illustrates the innovative use of immune checkpoint inhibitors and radiotherapy in response to tumor resistance.

Case Report: 59-year-old female patient presented with complaint of swelling in the hard palate that have been progressively evolving for five months. Intraoral examination revealed a non-tender blackish pigmented lesion covering the entire mucosal palatal region. This sessile growth was hard in consistency and measured around 6 x 5 cm. Neck examination did not reveal any palpable lymph nodes. Oral cavity magnetic resonance imaging showed a mass measuring 7 x 5 cm, developing from median palatine bone, extending beyond the oral cavity and reaching the tongue, pushing the uvula backwards. Lytic extension to the palatine and maxillary bone was noted. Excision biopsy of the lesion was performed. The histopathological examination showed atypical epithelioid melanocyte cells. The lesion was considered non operable because of its extensive nature. The patient received eight cycles of Nivolumab. Clinical and radiological progression, notably an increase in volume tumor and appearance of a trismus, was noted, thus indicating palliative radiotherapy. Target volume treated included the entire macroscopic palatal lesion with a 5 mm margin. The prescribed dose was 30 Gy delivered in 10 fractions. The irradiation technique used was 3D technique. After a 10-month follow-up, we noted a regression of tumor volume with subjective improvement of trismus and dysphagia reported by the patient.

Conclusion: Oral Malignant Melanoma is a rare and challenging disease despite advancements in treatment modalities. We reported a case of oral malignant melanoma that progressed under nivolumab. Radiotherapy emerges as a crucial option for local control with a notable impact on quality of life.

10. Clinical and ethical challenges regarding fertility in patients undergoing radiotherapy

Mani Y, Ben Abderrahim S, Kedhaouria N, Turki E
Forensic Medicine Department, Ibn El Jazzar University Hospital, Kairouan, Tunisia

Introduction: Oncology is a rapidly advancing field and radiology is improving every day showing better survival rates and outcomes among patients with cancer. However, alongside its therapeutic benefits, radiotherapy brings significant challenges, most overlooked is fertility preservation. We aimed to discuss the Tunisian legal

framework allowing the gametes conservation for patients undergoing radiotherapy as well as the associated ethical dimensions.

Methods: We conducted a lecture on the current legislation aimed at protecting reproductive health before, during, and after radiotherapy. We also reviewed the ethical considerations in the implementation of fertility preservation interventions through a literature review.

Results: In Tunisia, Law n° 2001-93 of August 7, 2001, on reproductive medicine provides a framework for the medical procedures involved in reproductive medicine, its activities, and practice methods. The law authorized gamete freezing only for married couples with infertility problems. This authorization was later extended on an exceptional basis to unmarried people undergoing treatment or those preparing to undergo a procedure that could affect their ability to procreate. These frozen gametes can only be used subsequently within the framework of a legitimate conjugal union. The gametes frozen in this way will be conserved for a maximum period not exceeding five years, which may be renewed for the same period upon written request from the patient. On expiry of this period, and without renewal of the request, these gametes must be destroyed. From an ethical standpoint, it was found that fertility concerns are increasingly recognized as an issue in this patient group. Furthermore, the notion of patient autonomy; informed consent; and equitable distribution of resources were identified as key issues that needed to be discussed.

Conclusion: By addressing the clinical, legal, and ethical aspects of fertility preservation when undergoing radiotherapy, we aim to establish informed decision-making and therapeutic strategies that conserve not only the patient's medical needs but also their reproductive health.

11. Assessment of depression, anxiety and stress on cancer patients during a week of radiotherapy

Ghommidh A, ChamsiA, Tbessi S, Benali B, Yazid D, Abdellatif I, Bettaieb O, Belajouza S, Bouzid N, Tebra S

University of Sousse, Faculty of Medicine Sousse, Farhat Hached Hospital, Radiation Oncology Department, Sousse, Tunisia

Introduction: Depression and anxiety are the most common psychiatric disorders associated with cancer. Radiotherapy (RT) is a tiring daily treatment and may increase the risk of those troubles. We aim to evaluate the prevalence of depression anxiety and stress among patients undergoing treatment with RT.

Patients and Methods: A cross-sectional study including 25 patients undergoing daily RT in the radiation oncology department, Farhat Hached Hospital, Sousse, Tunisia, during a week in march 2024. The depression anxiety and stress were assessed via DASS-21 scale (Depression Anxiety and Stress Scale).

Results: The median age was 53 years old [37-80] and the sex ratio was 0.3. The predilection tumor sites were breast and nasopharynx equally in 26%, cervix (13%) and digestive tract (17%) respectively. Eighty six percent had more than 3 sessions of RT. Sixty percent of the sample had mild to moderate depressive disorder ($D \geq 10$) and none had severe depression. Severe and moderate anxiety were found in 13% and 82% of cases respectively. Only 1 patient was affected by stress. Depressive disorders were higher in females patients ($p=0.02$) and anxiety was more frequent in males ($p<0.01$). Age >40 years old ($p=0.01$) as well as the number of sessions greater than 3 ($p=0.01$) were significant predictors of depression.

Conclusion: Our series showed that cancer patients are exposed to several stressful events that can affect their emotional and psychological health. Daily RT sessions may intensify depressive disorders more likely in females and patients aged over 40 years old.

12. Sleep Quality and Radiotherapy : prevalence of sleep disorders within patients ongoing radiotherapy

D Yazid, A Ghommidh, S Tbessi, I Abdellatif, A Chamsi, I Meddeb, O Bettaieb, S Belajouza, N Bouzid, S Tebra

University of Sousse, Faculty of Medicine Sousse; Farhat Hached Hospital, Radiation Oncology Department, Sousse, Tunisia

Introduction: Informed patient consent is a legal requirement for all medical treatment, particularly for patients undergoing radiotherapy. However, the information and consent of patients suffering from a pathology with a poor prognosis often raises numerous ethical and legal questions. We aimed to study the legal aspects of patient consent in the radiotherapy field and discuss the main ethical issues involved.

Methods: We reviewed the main Tunisian legal texts and ethical guidelines governing patient consent and information in radiotherapy.

Results: In Tunisia, information and consent are governed by the patient Charter and Decree no. 81-1634 of November 30, 1981, on the general internal regulations of hospitals. The patient charter clearly defines the doctor's duty to inform the patient about the diagnosis of the disease, the purpose and risks of the proposed investigations, the expected benefits and possible side effects of treatment, and the monitoring procedures. Informed consent requires that information should be clear, fair, and appropriate. This includes prior information for radiotherapy sessions. To provide written proof of the information provided by the doctor, informed consent forms have been introduced on the initiative of certain radiotherapy boards. Thus, it is now common practice to find in medical files documents signed by the patient, attesting to his or her full information and the informed nature of his or her choice. However, these forms are only a complement to oral information and are not mandatory. Yet can we speak of free consent in the case of patients distressed by their illnesses, sometimes forced to opt for aggressive treatment? Should we respect the autonomy of a patient at the end of life who takes refuge in social and relational denial? Should we respect the refusal of care by a patient already weakened by cancer?

Conclusion: Consent to care for cancer patients undergoing radiotherapy is a fundamental right of the patient and a duty of the doctor. Legal and ethical principles must be respected, especially in the case of cancer patients who may be at the end of their lives.

13. The esophagus is it an organ at risk in ultrafractionated local breast irradiation (Fast Forward)?

Ghommidh A, Chamsi A, Tbessi S, Meddeb I, Yazid D, Abdellatif I, Bettaieb O, Belajouza S, Bouzid N, Tebra S

University of Sousse, Faculty of Medicine Sousse, Farhat Hached Hospital, Radiation Oncology Department,, 4000, Sousse, Tunisia

Introduction: Postoperative ultrafractionated radiotherapy (RT) has shown its effectiveness in terms of reducing the risk of breast cancer relapse. As the esophagus is an adjacent organ, the risk of radiation esophagitis (RE) may be increased. We aim to assess the incidence of RE as well as the esophagus dose received during ultrafractionated local breast RT without lymph nodes irradiation.

Patients and Methods: We retrospectively reviewed 15 patients treated for localized breast cancer (T1,2N0M0) in the radiation oncology department, Farhat Hached Hospital, Sousse, Tunisia during the year 2023.

Results: The mean age of patients was 62 years [46-80Years]. Tumors were left sided in 46% and were classified as T1N0M0 and T2N0M0 in 28.5% and 71.5% respectively. The majority (66,66%) underwent

tumorectomy with sentinel lymph node. All patients received a 3-D adjuvant RT at a dose of 26 Gy in 5 fractions (5.2 Gy/fr) on remaining breast/chest wall, without lymph node irradiation with boost on the tumor bed at a dose of 10 Gy in 5 fractions in 5 cases (33%). The results of esophageal dosimetric parameters showed that dose constraints at the esophagus level were respected. The average maximum dose was 0.195 Gy [0.05-0.341Gy] and V20 Gy mean around to 0. After an average time of 5 months [1-14 months], no patient reported clinical symptoms of RE.

Conclusion : The esophagus D max<69 Gy and v20<45% were largely respected in our series indicating that RE is uncommon in patients with breast cancer undergoing ultrahypofractionated RT without lymph nodes irradiation. Therefore, we don't recommend to consider oesophagus as organ at risk in this area because it's well spared and constraints cannot be exceeded.

14. Adenocarcinoma of the sphenoid sinus : A case report

Friaa F, Ghorbel A, Mousli A, Amor T, Yousfi A, BenZid K, Nasr C

Radiotherapy Department, Salah Azaiez Institute, Tunisia

Introduction: Primary adenocarcinoma of the sphenoid sinus is an exceedingly rare malignancy with limited documented cases in the literature. We present a case report of a patient diagnosed with this uncommon tumor.

Case Presentation: A 28-year-old female with no medical history and with no history of exposure to wood dust or tannin, presented with persistent and isolated retro orbital headache. A brain CT scan revealed locally aggressive osteological expansive process centred on the body of the sphenoid bone, invading the upper wall of the cavum and extending into the lumen and choanae, with intra-sinus extension eroding the upper part of the clivus without any sign of endocrine extension, invading the posterior wall of the nasal septum. Biopsy of the cavum and histological examination showed low-grade papillary nasopharyngeal adenocarcinoma. MRI showed a mixed occupying process centred on the base of the skull and pedicled from the roof of the nasopharynx, with a cystic component and reshaped contents. Histopathological examination following surgical resection confirmed the diagnosis of primary papillary adenocarcinoma of the sphenoid sinus. The patient will undergo external radiotherapy using Volumetric Modulated Therapy (VMAT) technique, at a dose of 66 Gy.

Conclusion: The sphenoid sinus may be the starting point for primary malignant tumors of different histological types. Further research and documented cases are needed to elucidate optimal management strategies and outcomes for this rare malignancy.

15. Case report of primary breast angiosarcoma and review of literature

Tbessi S, Meddeb I, Yazid D, Abdeltif. I, Ben Ali B, Chamsi A, Bettaieb O, Kenoun S, Bouzid N, Tebra S

Cancer Radiotherapy Department, F. Hached hospital, Sousse, Tunisia

Introduction : Angiosarcoma of the breast (BA) is a rare malignant breast cancer primarily affecting younger women. It comprises approximately 0.04% of all breast cancers and 8% of breast sarcomas. This malignancy can arise spontaneously without identifiable risk factors or develop as a consequence of prior radiation therapy, known as secondary breast angiosarcoma. Typically, primary breast angiosarcoma manifests as a rapidly growing palpable mass, with mean tumor sizes ranging from 5.7 cm to 7.3 cm, as reported in previous studies.

Case presentation : We report the case of a 36-year-old patient who presented urgently to our radiotherapy department for spinal cord compression at the D2 to D12 levels. The patient had been followed up for

right breast mastodynia. She underwent breast ultrasound and mammography, revealing a large heterogeneous tissue mass occupying almost the entire right breast, poorly vascularized on Doppler imaging, measuring 11 by 7 centimeters. A biopsy was performed, confirming poorly differentiated angiosarcoma of the breast. Initial staging revealed pulmonary and bone metastases. Mastectomy was performed. During her chemotherapy appointment, the patient presented with paraplegia and urinary incontinence. Spinal MRI showed secondary compression at the level of D2 and D12 with total central canal invasion, causing circumferential compression of the spinal cord. Corticosteroid therapy was initiated along with a flash decompressive radiotherapy dose of 8 Gy, but the compression was found to be irreversible.

Conclusion: this case highlights the aggressive nature and diagnostic challenges associated with angiosarcoma of the breast, particularly in the context of spinal cord compression. Despite prompt diagnosis and initiation of therapy, the irreversible neurological complications underscore the urgency for early detection and aggressive management strategies for this rare malignancy. This case serves as a reminder to clinicians to maintain vigilance for rare malignancies, such as angiosarcoma of the breast, especially when encountering atypical clinical presentations or rapid disease progression.

16. Para testicular myxoid liposarcoma : a case report and a review of the literature

Tbessi S¹, Meddeb I¹, Ghommidh A¹, Yazid D¹, Abdeltif I¹, Chams A¹, Lajmi Z^{2,3}, Hmissa S², Bettaieb O¹, Kenoun S¹, Bouzid N¹, Tebra S¹

- 1) Cancer Radiotherapy Department, F. Hached hospital, Sousse, Tunisia
- 2) Pathology Department, Sahloul Hospital, Sousse, Tunisia
- 3) Research Laboratory LR21ES03, Medicine Faculty of Sousse, Tunisia

Introduction: The paratesticular liposarcoma develops from the fatty tissue surrounding the spermatic cord and covers the testicle and epididymis. It is an extremely rare pathological entity. Approximately 200 cases have been reported in the literature, but their incidence has been slowly increasing

Case Presentation: We report the case of a 60-year-old male with no significant medical history how presented with a painless right scrotal swelling involving over 2 years. Imaging studies revealed an enlarged right testicle with suspicious features on ultrasound. Subsequent high inguinal orchidectomy confirmed the diagnosis. The Final pathology report identified Low-grade myxoid paratesticular liposarcoma on the right side. Tumor size: 13 cm in greatest dimension. The tumor is in contact with the ink and the Spermatic cord margin was clear. Postoperative Doppler ultrasound showed no evidence of local recurrence at 10 weeks postoperatively. Since the tumor size is significant and R1 resection, we decided to administer adjuvant radiotherapy

Conclusion: Prompt diagnosis and appropriate management, including radical orchidectomy, remain crucial for favorable outcomes in paratesticular liposarcoma cases. Despite the rarity, understanding and addressing the challenges in diagnosing and treating these tumors are essential for improving patient outcomes. Further research is needed to optimize clinical management strategies for this rare pathological entity.

17. A familial case of nasopharyngeal carcinoma: A rare genetic predisposition

Benali B, Chamsi A, Tbessi S, Gommidh A, Yazid D, Abdellatif I, Bettaieb O, Belajouza S, Bouzid N, Tebra S

University of Sousse, Faculty of Medicine Sousse, Farhat Hached Hospital, Radiation Oncology Department, 4000, Sousse, Tunisia

Introduction: Nasopharyngeal carcinoma (NPC) is the second most common neoplasm of head and neck in Tunisia. While environmental factors such as Epstein-Barr virus infection and dietary habits are implicated in its pathogenesis, the role of genetic predisposition remains an area of active investigation.

Patient and methods: We report two cases of NPC within a single-family group, suggesting a potential genetic predisposition to this malignancy treated in the radiation oncology department, Farhat Hached hospital, Sousse, Tunisia in 2017 and 2022.

Case report: A 43-year-old male complained of a left nasal obstruction and headache. The clinical, radiological and anatomopathological examinations revealed undifferentiated nasopharyngeal cancer (UCNT) staged T4N2M0. He was treated with primary chemotherapy (CT) followed by concomitant CT-RT at a dose of 70 Gy in 35 fractions (2 Gy/fraction). After 7 years of follow up, the patient remained disease free.

The father, meanwhile, he was aged 75-year-old. He presented in our department 5 years later with bilateral hypoacusis, nasal obstruction and epistaxis. Initial nasofibrosopic examination found budding tissue process filling the nasopharyngeal postero-superior wall. The diagnosis of NPC was histologically confirmed and was staged as T2N2M0. He was proposed for induction CT followed by concomitant CT-RT but he refused the treatment. Currently, he is monitored regularly in our department. A further familial evaluation uncovered 3 NPC cases among first, second and third-degree relatives suggesting familial aggregation. While genetic analysis was not performed due to logistical constraints, the familial clustering of cases suggests a potential genetic predisposition to the disease.

Conclusion: This report highlights the importance of recognizing familial patterns in NPC and the potential role of genetic factors in its pathogenesis. Future research directions should include comprehensive genetic analysis to elucidate the underlying mechanisms contributing to familial NPC susceptibility.

18. Bladder urothelial carcinoma recurrence revealed by small bowel obstruction: A case report

Jelassi MA¹, Mzoughi M¹, Chahed M², Touffahi M¹, Youssef S²

- 1) Urology Department –Fattouma Bourguiba Teaching Hospital of Monastir
- 2) General and Digestive Surgery Department –Farhat Hached Teaching Hospital of Sousse

Introduction : Bowel obstruction is a surgical emergency defined as a partial or complete blockade of bowels lumen. Bowel obstruction's most common etiology is post-surgical adhesions. Small or large intestine invasion by a non-digestive abdominal tumor, in particular a non-digestive neoplastic recurrence, is a rare cause of intestinal obstruction.

Case report: We report the case of a 68-year-old heavy-smoking man who underwent radical cystoprostatectomy and left nephro-ureterectomy in 2019 for a non-metastatic invasive pyelic and bladder urothelial carcinoma, with cutaneous urinary diversion of the right kidney. 4 years later, the patient presented to the Emergency Department with acute bowel obstruction. Abdominal CT-scan concluded to acute intestinal obstruction, caused by a pelvic mass invading a segment of proximal jejunum. Open surgical exploration confirmed acute small intestine occlusion and showed a suspicious jejunum-invading mass, located in the cystoprostatectomy field. These findings were in favor of a local recurrence of the previously treated bladder neoplasm. In order to remove the neoplastic obstacle, patient underwent an en bloc resection of the jejunal segment and the mass, with jejunal end-to-end anastomosis. Surgical field was identified by surgical clips, in case post-operative radiotherapy was necessary. Histopathological examination of the specimen concluded to a locally-invasive bladder urothelial carcinoma

recurrence. The case was discussed in MTM Post-operative radio-chemotherapy was judged necessary.

Conclusion: Urothelial carcinomas are feared for the risk of recurrence and tumor progression. Strict and regular follow-up of treated patients is required. Diagnosis and management of bladder cancer recurrence, at the stage of complications, such as acute bowel obstruction, is challenging.

Bladder cancer recurrence is often discovered at the stage of loco-regional or systemic extension of the disease. Randomized multicenter clinical trials are required to codify bladder cancer recurrence management, which eventually involves radio and/or chemotherapy.

19. Breast metastases from medullary thyroid carcinoma: A case report

Attia N, Ben Zid Kh, Mokrani C, Ayadi H, Mousli A, Abidi R, Nasr CH

Cancer Radiotherapy Department, Salah Azaiez Institute, Tunis, Tunisia.

Introduction: Metastatic breast localization secondary to solid cancers is rare, accounting for only about 2% of all malignant breast tumors. Breast metastases secondary to medullary carcinoma of the thyroid are even more exceptional, constituting only 1% of the entirety of this entity.

Methods: We describe the case of a patient with bilateral metastatic breast recurrence of medullary carcinoma of the thyroid.

Case Report: A 25-year-old patient with a family history of breast neoplasia, diagnosed with medullary carcinoma of the thyroid in 2020. She underwent total thyroidectomy with bilateral functional neck dissection and bilateral mediastino-recurrent lymph node dissection. 6 months post-operatively, she presented with cervical lymph node recurrence, for which she had bilateral functional neck dissection followed by radiotherapy to the cervical lymph node regions at a dose of 66 Gy. In 2022, a right breast mass was identified on a CT scan performed as part of the evaluation assessment. Breast ultrasound revealed a benign lesion, localized in the supero-external quadrant of the right breast, classified as ACR 3. Monitoring by breast ultrasound every 6 months was recommended. One year later, the breast assessment revealed the presence of 6 masses (3 on the right and 3 on the left breast), requiring histological verification by micro-biopsy. Histopathological and immunohistochemical examination confirmed the breast localization of medullary carcinoma of the thyroid. An octeoscan was performed as part of the distant staging assessment, which did not reveal any other metastatic lesions. After discussion in a multidisciplinary meeting, the patient was proposed for a tumorectomy of all lesions followed by breast radiotherapy and Cabozantinib as systemic treatment.

Conclusion : Although rare, secondary breast metastases from extramammary malignant tumors should not be overlooked and should be considered in the presence of personal history of neoplasia. Increased vigilance and multidisciplinary management are necessary to diagnose and treat these cases, to ensure the best outcomes for patients.

20. Intestinal-type sinonasal adenocarcinoma: A sporadic case

Halleb H, Chamsi A, Souissi M, Sabrine Tbessi S, Delia Yazid D, Abdellatif I, Bettaieb O, Belajouza S, Bouzid N, Tebra S

University of Sousse, Faculty of Medicine of Sousse, Farhat Hached University Hospital, Radiation Oncology Department, Sousse, Tunisia

Introduction: Sinonasal Intestinal-type adenocarcinoma (ITAC) is uncommon. It is closely related to certain occupations and exposure to inhaled wood dust. We aim to study the clinicopathologic features and the treatment strategies of this rare entity.

Materials and methods: We describe a sporadic case of ethmoidal ITAC treated in the radiation oncology department, Farhat Hached hospital, Sousse, Tunisia in 2013 and 2018.

Results: A 55-year-old man, a farmer without history of wood dust exposure, presented with a complaint of nasal obstruction for four months. A computed tomography (CT) scan revealed a right anterior ethmoidal tumor extending into the nasal cavity, causing obstruction of the osteomeatal complex. The biopsy identified an ethmoidal ITAC. A right posterior ethmoidectomy via a lateral rhinotomy followed by postoperative radiotherapy (RT) at a dose of 55.8 Gy in 31 fractions (1.8 Gy/fraction) were performed. Four years later, the patient presented with epistaxis and a biopsy specimen confirmed an ITAC recurrence localized in the nasopharynx. He underwent an Intensity-Modulated RT at a dose of 60 Gy in 30 fractions. Unfortunately, follow-up detected tumor recurrence one year later. Therefore, he received palliative chemotherapy and remained alive and symptomless.

Conclusion: Due to its rarity, there is no standard treatment for sinonasal ITAC especially for irresectable local recurrences. A multimodal therapeutic approach based on complete surgical resection and post-operative RT is mandatory. Further studies are needed to identify the optimal schedule especially in a palliative setting.

21. Breast location of Darier and Ferrand dermatofibrosarcoma: A rare case report

Souissi M, Bettaieb O, Ben Ali B, Halleb H, Chamsi A, Sghaier S, Tbessi S, Belajouza S, Bouzid N, Tebra S.

Radiotherapy Department, CHU Farhat Hached of Sousse

Introduction: Dermatofibrosarcoma of Darier and Ferrand (DFS) is an exceptionally rare subtype of soft tissue sarcoma, particularly uncommon in breast cancer cases. Due to limited reported instances, optimal treatment strategies remain unclear, presenting challenges for clinicians.

Case Presentation: A 53-year-old patient with no significant medical history presented in July 2023 with a 6 cm nodule in the upper outer quadrant of the right breast. Initial examination revealed a hypochoic tissue mass with microcalcifications, along with skin thickening and multiple satellite nodules. A biopsy confirmed the diagnosis of a phyllodes tumor of the right breast. The patient underwent surgery on November 24, 2023, undergoing a wide local excision of the right breast with reconstruction. Pathological examination revealed a 12 cm grade I DFS, with clear surgical margins located 1 cm from the tumor tissue. Immunohistochemistry showed positivity for CD34 and negativity for PS100. The tumor was classified as pT3Nx, and staging work up is ongoing. The patient is scheduled to receive post-operative radiotherapy.

Conclusion : This case highlights the diagnostic complexity and therapeutic uncertainties surrounding DFS, with prognosis largely dictated by local malignancy and a high potential for recurrence. Successful surgical intervention was achieved, but the adequacy of surgical margins remains a subject of controversy.

22. Radiotherapy of dermatofibrosarcoma protuberans

Bahri M^{1,2}, Daghfous Y¹, Turki H³, Boudawara T⁴, Ben Salah H¹, Daoud J¹

1) Radiotherapy Oncology Department of CHU HB Sfax,

2) Radiotherapy Oncologist of CHU Gabès,

3) Dermatology Department of CHU HC Sfax,

4) Anatomopathology Department of CHU HB Sfax

Introduction: Dermatofibrosarcoma protuberans (DFSP) is a rare, slow-growing, dermal soft-tissue tumor. It is characterized by a high incidence of local recurrence and posed challenges to treatment. Here we present the management of DFSP and we analyze the outcomes of patients treated with radiotherapy.

Methods: This was a single-institution, retrospective review of patients with primary or recurrent DFSP who underwent radiotherapy between 1995 and 2023 in our Radiotherapy Oncology Department.

Results: Eight patients were included. The mean age was 51 years. Five patients were female. Six lesions (75%) were located on the trunk. Four patients had only one surgery, 3 operated twice and 1 operated 3 times. The average time between the 2 surgeries was 22 months. The type of surgical excision was limited excision in 5 patients. All patients had radiotherapy at a dose of 50-54 Gy with boost of 10-14 Gy for 4 patients. The mean follow-up was 81 months (10-260). There was no case of recurrence. Recurrence-free survival was 86 months and 58 months for patients with recurrent disease.

Conclusion: In our series, among the operated patients 50% presented a local recurrence before RT. There was no recurrence in irradiated patients despite limited excision in 5 patients. So radiotherapy is an effective treatment option for DFSP patients with positive or limited post-operative margins and recurrent disease.

23. Effect of Palliative Radiotherapy on Quality of Life and Pain in Patients with Bone Metastases

Attia N, Mousli A, Ben Zid Kh, Ghorbel A, Mokrani C, Kaabia W, Ayedi H, Abidi R, Nasr Ch.

Cancer Radiotherapy Department, Salah Azaiez Institute, Tunis, Tunisia.

Introduction: Palliative care is defined by the World Health Organization as an approach that improves the quality of life of patients and their families. Bone metastases are common in patients with advanced cancer, causing pain and other complications such as fractures and compression. Palliative radiotherapy plays a crucial role in the management of these conditions.

This study aims to evaluate the impact of analgesic radiotherapy on the quality of life of patients with bone metastases, using the EORTC QLQ-C15 PAL.

Methods: Twenty patients received analgesic radiotherapy in the oncological radiotherapy department of the Salah Azaiez Institute were selected in this prospective study. Three weeks after treatment, these participants underwent an assessment of their quality of life using the specific EORTC QLQ-C15 PAL questionnaire.

Results : The median age of patients was 54 years [28-80]. Among them, 60% were men. Breast cancer was the most common primary cancer (35%), followed by prostate cancer (20%), bronchopulmonary cancers (15%), clear cell renal tumors (10%) and other rare locations represented by 20% of cases. Among the irradiated locations, the spine was the most frequent location in 55% of cases followed by lesions of the pelvis, sacrum, shoulder and finally the ribs. Radiotherapy was delivered in a single fraction in 65% of patients and hypofractionated (20 Gy in five fractions or 30 Gy in ten fractions) in 25% of patients.

Pain assessment at three weeks revealed a complete response in only 5% of patients, while 60% reported a partial response. In 7 patients, the pain remained stable and none experienced worsening pain. Similarly, a reduction in the morphine dose was noted in 10 patients (50%). Constipation was relieved in 45% of patients. Additionally, improvement in insomnia was observed in 13 patients (65%). The median scores for quality of life and physical and emotional functions were 51% [40-62%], 40% [36-44%] and 77% [63-91%], respectively.

Conclusion : These results highlight the crucial role of palliative radiotherapy in the effective control of pain in patients with bone metastases in the palliative stage, as well as its significant impact on improving their quality of life. These observations reinforce the importance of considering radiotherapy as an essential component of palliative care.

24. Assessment of dosimetric outcomes using the Fast Forward Radiotherapy protocol for breast cancer treatment

Ben Ali B, Bettaieb O, Kaabia W, Sghaier S, Ghommidh A, Chamsi A, Yazid D, Tbessi S, Belaajouza S, Bouzid N, Tebra Mrad S.

Radiotherapy Department, Farhat Hached hospital, Sousse, Tunisia.

Introduction: Radiotherapy is crucial in breast cancer management, with emerging hypofractionated regimens like FAST FORWARD aiming to improve care quality while maintaining efficacy. Our study evaluates dosimetric outcomes in breast cancer patients treated with radiotherapy following the FAST FORWARD protocol.

Methods and patients: This retrospective study included 14 breast cancer patients treated at Radiotherapy department, Farhat Hached University Hospital between January 2023 and March 2024. All the patients underwent postoperative radiotherapy of the breast or chest wall using 3D conformal radiotherapy, delivering a dose of 26Gy in 5 fractions. Patients who underwent breast-conserving treatment received a complementary dose to the tumor bed, delivered at a dose of 10 Gy over 5 fractions. We retrospectively recorded dosimetric parameters including heart and lung doses, Planning Target Volume (PTV) coverage, and the maximal dose received by PTV (Dmax).

Results: A total of 14 patients were included in this study, with a median age of 62.07 years (46 - 80 years), treated with conservative surgery in 71.4% of cases, and 57.1% of tumors were classified as pT2N0M0. 42.9% of patients were treated for a left breast cancer. The most common histologic type was CCNS (71.4%). Among the molecular subtypes, 50% of patients presented with Luminal B subtype, while 28.6% were classified as Luminal A. 2 patients (14.3%) presented a Triple-Negative Breast Cancer (TNBC), and one patient presented with Luminal B Her2+++ breast cancer. Dosimetric results showed the mean volume of the heart receiving more than 1.5Gy was 7.66% (0.04%-23.65%), median volume of the ipsilateral lung receiving more than 8GY (V8Gy) for the lung was 12.40% (6%-16.48%). The coverage of more than 95% of the PTV was $\geq 90\%$ in 92.85% of cases and was optimal ($\geq 95\%$) for 50% of patients with a mean V95% of 94.64%. Mean V105% and V107% were 5.61% and 0.81% respectively. Dmax ranged from 105% to 110.5%, with a median value of 106.69%.

Conclusion: Our findings demonstrate that the dosimetric objectives outlined in the Fast Forward protocol were met, further affirming its efficacy and reliability in clinical practice.

25. Unusual Isolated Localization of Kaposi Sarcoma: A case report

Hadhri I, Belkacem O, Mestiri S, Krifa M, Lajmi Z, Hmissa S

Pathology Department, Sahloul Hospital of Sousse, Tunisia

Introduction: Kaposi's sarcoma (KS) is frequent among HIV patients, characterized by low-grade vascular tumors mainly affecting mucocutaneous sites. However, KS at the base of the tongue is a rare localization, with only a few documented cases despite approximately 5% of transplant patients developing KS, of which only 2% involve oral KS.

Methods: Herein, we present a case of Kaposi sarcoma located in the tongue. The highlights in this case included not only the rare incidence of this tumour, but also its localization, which resulted in uncertainty in diagnosis and preoperative planning.

Results: We report a case of a 64-year-old man presented with a budding lesion localized to the tongue. The patient underwent a partial glossectomy and a left functional neck dissection. On macroscopic examination, the lesion was fungating with a brownish appearance, measuring 3.3 x 1.9 cm and located at the lateral border of the tongue. Histopathological examination revealed a widely ulcerated vascular

proliferation on the surface, replaced by a fibrinoleukocytic coating. This proliferation exhibited a nodular architecture composed of numerous vascular structures of varying sizes and fissures lined by endothelial cells. Additionally, there was a discreet spindle cell component. The estimated mitotic index was 7 mitoses per 10 high-power fields. An immunohistochemical study was performed, showing an expression of HHV8 and CD34 by the neoplastic cells. The lymph node dissection revealed the presence of metastasis in 22 out of the 30 lymph nodes sampled. The surgical resection margins were clear.

Conclusion: In conclusion, Kaposi's sarcoma, a tumor commonly seen in immunocompromised individuals with frequent cutaneous involvement, warrants attention when occurring in rare locations such as the tongue. This underscores the need for meticulous histopathological examination and appropriate management.

26. An unusual simultaneous association of whole abdomen and bilateral pulmonary irradiation in relapsed pediatric Wilms tumor

Chamsi A, Bouzid N, Tbessi S, Sghaier S, Yazid D, Bettaieb O, Abdellatif I, Belajouza S, Tebra S

University of Sousse, Faculty of Medicine Sousse, Farhat Hached Hospital, Radiation Oncology Department, 4000, Sousse, Tunisia

Introduction: The majority of pediatric Wilms' tumor (WT) relapses occur in the lungs. The management of recurrent disease, the therapy late effects and the main indicators of salvage treatment failure remain an important issue of concern.

Materials and methods: we describe an unusual case of simultaneous association of whole abdomen and bilateral pulmonary irradiation (RT) in relapsed pediatric WT treated in the radiation oncology department, Farhat Hached hospital, Sousse, Tunisia in 2024.

Results: A child aged of 2 years 5 months was diagnosed with WT. She underwent preoperative chemotherapy (CH) followed by right nephrectomy and adjuvant CH. Nine months after surgery, a bilateral lung metastasis was occurred. She had whole abdomen RT at a dose of 15 Gy in 10 fractions and lungs RT at a dose of 12 Gy in 8 fractions (1.5 Gy/fraction) with acceptable toxicities. She remained disease-free for 1 month of follow up but 2 months later, she presented with brain and lungs relapse. A metastasectomy of the brain lesion followed by CH will be scheduled.

Conclusion: Evidence of how to properly administer RT at WT relapse is a challenge. A standardized therapeutic approach based on up-date recommendations and a long-term follow-up are mandatory.

27. Compliance with dose constraints in hypofractionated radiotherapy for breast cancer

Bouzid N, Zanzouri R, Amri B, Naija B, Bettaieb O, Chamsi A, Tbessi S, Kanoun S, Tebra S

Radiotherapy Department, CHU Farhat Hached, Sousse, Tunisia

Introduction : In recent years, hypofractionated radiotherapy for breast cancer has become the standard. Our aim is to assess compliance with dosimetric constraints in hypofractionated radiotherapy (RT) for breast cancer.

Methods : A descriptive, analytical study carried out with 70 breast cancer patients after radical surgery, treated with hypofractionated locoregional RT delivering a dose of 40 Gy in 15 fractions over 3 weeks, using three-dimensional conformal RT, at the Oncological Radiotherapy department of the Farhat Hached Hospital, Sousse, Tunisia between 2022 and 2023.

Results : The mean age was 52.4 [29-75]. 51.4% of patients had right-sided tumours. Sufficient dose coverage of target volumes was achieved for 78.57% of cases (PTV-V95%>95%). The mean PTV-V95% was

92.42% [68.16-100]. However, the maximum acceptable dose was exceeded (>110%) in 32.86% of cases, and the average Dmax was 44.6Gy (110.7%) [106.8-117%]. For the heart, the mean Dmoy was 1.68Gy [0.3-4], and the dose was greater than 2.5Gy in 24.3% of cases. The average heart volume receiving 2% (V2%) and 10% (V10%) of the prescribed dose was 13.37% [0-30.44] and 3.4% [0-10.3], respectively. The heart receives fewer doses in case of right RT compared to left RT. The difference was significant for all studied parameters : Dmoy (1.19Gy vs 2.6Gy, p = 0.0001), V2% (9.8% vs 18.2%, p = 0.0001) and V10% (2.1% vs 5.9%, p = 0.03). Regarding the dose constraints in the ipsilateral lung, the mean lung volume receiving 12% (V12%) of the prescribed dose was 33.7% [23.9-47.9%], with a volume greater than 30% in 82.85% of cases. The mean V17% and V28% were 29.42% [20-33.11] and 18.21% [11.5-23.2], respectively. The analytical study showed that V12% was significantly greater in the case of left-sided tumors (p=0.003).

Conclusion : In the case of locoregional breast RT, it is often difficult to comply with dose constraints in the OAR, especially in the absence of respiratory-gated techniques. In our study, compliance with protocol dose constraints was found in 70% of cases.

28. Quality of life and return to professional activity after radiotherapy for nasopharyngeal cancer

Massoudi S, Bouzid N, Zanzouri R, Tbessi S, Belajouza S, Tebra S

Radiotherapy Department, CHU Farhat Hached, Sousse, Tunisia

Objective: The aim of our study is to evaluate the overall quality of life (QoL) and identify the factors favoring the return to professional activity in patients treated with radiotherapy for a nasopharyngeal cancer.

Methods: this is a retrospective and analytical study including 30 patients with nasopharyngeal cancer treated with radiotherapy (RT) in our department of oncologic radiotherapy in Sousse during the period [2020-2022]. The collection of data concerning the resumption of professional activity was ensured using a pre-established questionnaire. Overall quality of life was assessed using the EORTC QLQ-C30 questionnaire (version 3) Arabic version which includes 30 questions, divided into 3 scales: general health, functional health (physical, emotional, cognitive, functional and social aspects) and symptoms (fatigue, pain, insomnia, motion sickness and other symptoms). The scores on this scale range from 0 to 100. In the general and functional health scales, higher scores reflect better QoL. However, for the symptom scale, higher scores show more severe impairment.

Results: the median age was 45 years [18-68 years]. The tumor was classified stage (T3-T4) in 75% of cases. Lymph node involvement was present in 78% of cases. Treatment consisted of chemotherapy as neoadjuvant treatment for all patients followed by concomitant chemo radiotherapy at a dose of 70Gy in 35 (2Gy/fraction). The median duration of radiotherapy was 8 weeks. When evaluating the QoL, the median score was 76 [69-80] for general health, 80 [75-85] for functional health, and 29 [25-32] for symptom intensity. The average of the duration of the professional activity was 7 years±5 years. The median time off work was 12 months. The resumption of professional activity concerned 11 patients (45%) of cases, of which five patients (49%) returned to work after the first year of the end of radiotherapy. The use of work stoppage after recovery concerned five patients who developed local or distant recurrence. The main factors favoring the return to work were essentially material necessity in 75% of cases and the search for psychological support in 25% of cases. High educational level and a duration of work stoppage of less than 1 year are the predictive parameters of return to work (p =0.05), with a tendency to signification within patients with better overall QoL (p=0.06).

Conclusion: therapeutic advances in oncology radiotherapy have led to an increase in the number of cancer survivors in working adults presenting a nasopharyngeal cancer with a conserved overall QoL.

29. Nasopharyngeal cancer and level Ib irradiation in the prophylactic lymphnode volume: short and long-term toxicities ?

Massoudi S, Bouzid N, Zanzouri R, Tbessi S, Belajouze S, Tebra S

Radiotherapy Department, CHU Farhat Hached, Sousse, Tunisia

Introduction: Nasopharyngeal (NP) cancer is a lymphophile tumor requiring prophylactic cervical lymphnode irradiation when planning curative radiotherapy. Furthermore, irradiation of level Ib is not systematic and is indicated in specific situations. The aim of this study is to evaluate the acute and chronic toxicities of including the level Ib in the prophylactic lymphnode volume in the treatment of NP cancer.

Materials and methods: This is a retrospective, analytical study, including 34 patients treated for NP cancer during the period of [2019-2022] at the department of radiotherapy at Farhat Hached Hospital at Sousse.

Results: The median age was 45 years [18-75 years]. The tumor was classified stage T2, T3 and T4 in 41%, 20% and 39% of cases respectively. There was lymphnode involvement in 78% of cases (N1: 15% N2: 50% N3: 13%). Treatment consisted of neoadjuvant chemotherapy in all patients followed by concomitant chemoradiotherapy at a dose of 70 Gy in 35 fractions (2 Gy/fraction). Twenty-two patients (65%) had prophylactic irradiation of the level Ib in the cervical lymphnode volume at a dose of 54 Gy. The median duration of radiotherapy was 8 weeks. Acute toxicities were radiomucositis, radiodermatitis, oral candidiasis, dysphagia in 90%, 92%, 18%, 15% of cases respectively in the group of patients who had the level Ib irradiation with a trend towards significance in terms of radiomucositis in bivariate analysis ($p=0.06$) in comparison with the 2nd groupe. Concerning long-term complications, they were also more frequent in the 1st group in term of cervical fibrosis grade I, II (32% versus 15%), xerostomia grade I (55% versus 15%) or chronic dysphagia (18 % versus 8%). In bivariate analysis, the difference is significant between the two groups in terms of xerostomia ($p = 0.017$) and in terms of cervical fibrosis ($p = 0.014$).

Conclusion: The prophylactic cervical lymphnode volume in the context of curative radiotherapy for NP cancer must be well indicated according to the stage of the disease in order to limit subsequent toxicities that could affect the quality of life of these patients being most frequently within young population.

30. Bifocal Melanoma: A Rare Case Study of Colonic and Ileal Melanomas

BenHassine H, HadjTaieb A, Ben Jabra S, Chouch MA, Korbi I, Faouzi N

General Surgery Departement, CHU Fattouma Bourguiba

Introduction: Malignant melanomas are malignant tumors that develop from the pigment system. Colonic localization is characterized by its rarity, the absence of standardized management, and a poor prognosis.

Observation: An 83-year-old man with a history of perforated ulcer surgery in 1984 was admitted for acute intestinal obstruction. A 13 cm intraperitoneal mass with adrenal metastases was identified on CT scan. He underwent midline surgery, with intraoperative lesions in the mesentery of the transverse colon and the terminal ileum. Left colectomy with colo-colonic anastomosis and small bowel resection with small bowel-small bowel anastomosis were performed. Postoperative complications included a left hypochondrial collection requiring surgical drainage. Histological examination revealed a bifocal melanoma (colonic and ileal).

Discussion: Malignant melanoma is a rare condition, accounting for less than 1% of colonic cancers. It can occur at any age, with a peak incidence in the sixth decade, and a slight female predominance. Clinical symptoms are varied and nonspecific. Malignant melanomas exhibit diverse histological characteristics and can mimic other tumors, sometimes necessitating immunohistochemistry, especially in atypical forms like amelanotic melanomas. Melanoma is a polymetastatic disease primarily spreading through lymphatic and hematogenous routes. Due to a lack of clear consensus from randomized studies, therapeutic options mainly revolve around surgery. Chemotherapy and radiotherapy are used as palliative treatments, as their efficacy in curative management of melanoma is still under evaluation.

Conclusion: Clinical and endoscopic aspects initially suggested a gastrointestinal stromal tumor diagnosis, which was only differentiated through histopathological examination with immunohistochemistry. Despite advancements in oncology, the prognosis of melanomas remains grim due to delayed diagnosis and high malignant potential. Surgery currently dominates as the primary treatment modality.

31. Radiochemotherapy for locally advanced degenerated Verneuil disease of sacrococcygeal region

Harroum M, Chakka A, Haj Mahmoud K, Korbi I, Nomen F

General Surgery & Digestive Departement, CHU Fattouma Bourguiba, Tunisia

Introduction: Verneuil's disease or hidradenitis suppurativa (HS) is a chronic inflammatory and suppurative disease, mainly affecting the apocrine-bearing skin area. Like other chronic inflammatory disorders, squamous cell carcinoma can occur in the context of chronic inflammatory lesions of HS with a prevalence that can reach 4.6%.

Observation: We report the case of a 63-year-old man with a history of hidradenitis suppurativa for 37 years presenting with a coccygeal collection. On examination: Large loss of substance with indurated edges and several productive fistulous tracts. Pelvic MRI: Thickening tissue infiltrating the superficial and deep tissues of the sacrococcygeal region. This process measures 20*48 mm extending over 80 mm. Pathological examination: Well-differentiated keratinizing bifocal squamous cell carcinoma. Bone scintigraphy: discrete hyperfixation in the sacrococcygeal region related to local regional bone involvement, absence of secondary distant bone lesions. Given the extent of the lesion and secondary bone involvement, the patient underwent neoadjuvant radiochemotherapy with a good response.

Conclusion: The diagnosis and treatment of hidradenitis suppurativa are challenging. Concurrent radiochemotherapy remains the treatment of choice for better outcomes for degenerated hidradenitis suppurativa.

32. 3D Conformal Radiation Therapy for Kaposi's Sarcoma: Dosimetric Profile

Ben Salah H, Chikh MA, Bahri M, Njeh F, Farhat L, Sahnoun T, Daoud J

Radiotherapy Department, Habib Bourguiba Hospital Sfax, Tunisia

Introduction: The technique of irradiation of Kaposi's sarcoma is ancient. She uses a box in which the affected limb segment is placed and covered with rice. This soft tissue equivalent served as a comfortable, reproducible circumferential bolus to homogenize and increase the dose at the skin level. The objective of this work is to demonstrate the benefit of this method through a dosimetric study.

Patients and methods: 2 patients were treated with 3D radiotherapy using the rice box for Kaposi's sarcoma. The first is a man with diffuse damage to his right foot and leg. The second case is a woman with lesions on her left leg. Two CT scans in the treatment position were done for the 2

patients, one with the box filled with rice and the other with a box without rice. A contouring was done for the following volumes: box, limb, affected skin and then the limb-skin. Two opposite fields were used to deliver a dose of 30 Gy in 15 fractions of 2Gy to the entire box. The radiation used was of the 6MV photon type. The distribution of the dose was studied with and without rice for the 2 cases.

Results: In treatment without rice, the skin was underdosed and the dose was inhomogeneous within the irradiated limb segment. In the case of a box filled with rice, the skin receives a homogeneous dose > 95% of the prescribed dose. However, the inside of the limb segment also receives a homogeneous dose of 95%.

Conclusion : The use of rice allowed to homogenize and increase the dose at the level of the skin.

33. Right colectomy with complete excision of the mesocolon for Cecum cancer

Ben Hassine H, Hadj Taieb A, Chaouch MA, Korbi I, Faouzi N

General Surgery Departement, CHU Fattouma Bourguiba

Introduction : The prognosis of right colon cancers depends mainly on the quality of lymph node dissection, which will have an impact on the risk of survival without recurrence and on mortality. Hohenberger created the 'Complete mesocolic excision' technique, through knowledge of a few anatomical landmarks, this technique offers a better quality of lymphatic tissue excision.

Observation : This is a 54-year-old patient, recently explored by a colonoscopy for anemia which showed an ulcero-budding process in the cecum. Pathological examination confirms the malignant nature of this tumor. After an assessment of extension and operability without anomaly, we operate on the patient with a right colectomy with complete excision of the mesocolon. The CME criteria for oncological radicality are as follows: preservation of the visceral fascia without lesion of the mesocolon, complete removal of lymph nodes, ligation of the vessels at their origin (Ileocolic, middle colic, colic, right colic), complete excision of lymphatic tissue along the right border of the MSV from the ileocolic vein to the gastrocolic venous trunk of Henle and preservation of the gastrocolic venous trunk of Henle

Conclusion: Complete excision of the mesocolon via a posterior laparoscopic approach is a feasible method with knowledge of vascular anatomy.

34. Acute radiation-induced skin toxicity in hypofractionated whole-breast irradiation : Predictive factors

Bouzid N, Zanzouri R, Amri B, Fayala R, Beltaieb O, Chamsi A, Tbessi S, Kanoun S, Tebra S

Radiotherapy Department, CHU Farhat Hached, Sousse

Introduction : Our aim is to assess acute radiation dermatitis rates in hypofractionated whole breast irradiation (HF-WBI) for breast cancer patients, and to analyze their correlation with dosimetric characteristics.

Methods : A retrospective, analytical study carried out with 54 breast cancer patients after conserving surgery, treated with hypofractionated radiotherapy (RT), delivering 40 Gy in 15 fractions over 3 weeks, with or without boost to the tumor bed, using three-dimensional conformal RT, at the Oncological Radiotherapy department of the Farhat Hached Hospital, Sousse, Tunisia between 2022 and 2023.

Results : The mean age was 55.8 [34-73]. 50% of plans covered Berg levels III/IV and internal mammary chain. 53.7% of patients received tumor bed boost of 13.35Gy in 5 fractions. Electrons were used in 57.4% of treatment plans. Three-dimensional field-in-field technique and wedge filters were used in 96.3% and 59.3% of treatment plans, respectively. The

mean Dmax was 107.3%. The mean WB-CTV and WB-PTV volumes were 809.7cm³ [50.4-2441.8] and 1000.5cm³ [104.3- 2755], respectively. The mean boost volume was 95.4cm³ [9.1-295.1]. The mean breast volume for each isodose group >107% and >110% were 1.5% [0-14] and 0.11% [0-2] respectively. The WB-V110 was 0% in 83.33% of plans. During RT, 46.3% and 3.7% of patients developed grade 1 and grade 2 acute skin toxicity, respectively. Two weeks after the end of RT, 4 patients (7.4%) presented no acute toxicity, while grade 1, 2, and 3 dermatitis rates were 40.7%, 50%, and 1.8%, respectively. No instances of grade 4 radiation dermatitis occurred. The late skin toxicity was correlated with age, patients aged greater than the median presented more toxicities (p=0.021), the additional boost delivery (p=0.05), Dmax (p=0.004) and WB-V110% (p=0.05). There was a trend for increased grade 2 dermatitis with use of electrons (p=0.055).

Conclusion : These results confirmed that HF-WBI is safe and well tolerated in most cases. In our experience, younger age, boost administration, Dmax and WB-110% seems to be important predictors for acute skin damage.

35. Subcutaneous Extra-Medullary Plasmacytoma: A Case Report

Attia N, Ben Zid Kh, Skouri M, Mokrani C, Ayedi H, Mousli A, Abidi R, Nasr Ch

Cancer Radiotherapy Department, Salah Azaiez Institute, Tunis, Tunisia.

Introduction: Solitary plasmacytoma is a monoclonal proliferation of malignant plasma cells, representing 3 to 5% of all plasmacytomas. Extrasosseous solitary plasmacytomas are localized in the upper respiratory tract in 80% of cases but can, rarely, affect other sites. Radiotherapy is a corner stone in the management of this condition.

Methods: We present the case of a subcutaneous extra-medullary solitary plasmacytoma treated at the radiotherapy department of the Salah Azaiez Institute.

Case Report: A 50-year-old female patient, with no significant medical history, presented in February 2023 with swelling in the right thigh. Upon initial examination, a subcutaneous mass measuring 4 cm in the longest axis, firm and hard, was palpated on the antero-internal aspect of the right thigh. MRI of the thigh revealed a mass in the subcutaneous fat in contact with the superficial fascia, measuring 33.5*20 mm and extending over 22 mm, with a hypo-intense signal in T1 and heterogeneous intermediate signal in T2. An echo-guided biopsy was performed, and histopathological and immunohistochemical studies confirmed an extra-medullary plasmacytoma. A distant staging scan with thoraco-abdomino-pelvic CT revealed no synchronous or secondary localization. The patient underwent surgical excision of the tumor, reaching the adherence plane of the fascia. Histopathological examination confirmed an extra-medullary plasmacytoma with clear surgical margins, with a narrow deep margin. Post operative MRI showed no residual tumor. Due to the narrow deep margin, the patient received post operative radiotherapy to the tumor bed, at a dose of 40 Gy in 20 fractions, with good tolerance.

Conclusion : Extrasosseous plasmacytoma is a rare condition that can affect any region of the body. Its treatment mainly relies on radiotherapy or surgery for certain locations.

36. Surgical Management Strategies for Pancreatic Neuroendocrine Tumors

Ben Hassine H, HadjTaieb A, Jallali M, Ben Jabra S, Korbi I, Faouzi N

General Surgery Departement, CHU Fattouma Bourguiba

Introduction: NETs represent 1.2% to 1.5% of all digestive tumors. The majority of affected patients are between 50 and 60 years old. Both men and women are equally affected. Most NETs occur sporadically, indicating

a non-familial nature. However, they can sometimes be part of familial endocrine neoplastic syndromes, such as multiple endocrine neoplasias and neurofibromatosis type I. The medical management of endocrine tumors is considered complex due to their rarity, varied anatomical and clinical presentations, and the iterative changes in their classification.

Observation: We report two cases: the first is a 41-year-old patient followed since 2012 for a 17 mm pancreatic neuroendocrine tumor where the decision was clinical and morphological surveillance. The second case is a 43-year-old patient diagnosed with an asymptomatic 2 cm neuroendocrine tumor who underwent enucleation and has been regularly monitored without signs of tumor recurrence.

Conclusion: The rarity and diverse anatomical-clinical presentations of pancreatic endocrine tumors explain the complexity in their management. Surgery is the only curative treatment for localized forms. The role of the pathologist is crucial, as their findings influence therapeutic decisions and patient follow-up. The management strategy for an endocrine tumor must be multidisciplinary and discussed within multidisciplinary team meetings.

37. Invasive undifferentiated sarcoma of the retroperitoneum, a therapeutic challenge

Jelassi MA, Ben Saad H, Mzoughi M, Bedoui Y, Touffahi M

Urology Department, Fattouma Bourguiba Teaching Hospital of Monastir

Introduction: Sarcoma is a rare aggressive soft-tissue malignant neoplasm. Retroperitoneal location of sarcoma is uncommon. Surgical resection of these tumors is the cornerstone of curative treatment, forming part of a more complex and multidisciplinary management process.

Case report: We report the case of a 66-year-old man, with no relevant medical history, complaining of chronic right low back pain. Partially relieved by level-2 analgesics, the pain was progressively worsening since 3 months, within a context of Deterioration of General Condition (DGC). Physical examination showed right lumbar tenderness, and involuntary 10-kg weight loss. Inflammatory anemia and thrombocytosis were found at complete blood count (CBC). Thoracic-abdominal-pelvic enhanced CT-scan revealed a right poly-lobed 17-cm retroperitoneal mass, with inhomogeneous contrast enhancement, and close anatomical relations with the following structures: right kidney and renal pedicle, liver IVth segment, anterior circumference of inferior vena cava, diaphragmatic left crus, left psoas muscle and pleura. CT-guided biopsy of the retroperitoneal mass was performed days later. Histological examination concluded to undifferentiated malignant tumor of the retroperitoneum. Immunohistochemistry was unremarkable. Thus, undifferentiated retroperitoneal sarcoma was the definitive exclusion diagnosis. The case was discussed in the weekly Multidisciplinary Team Meeting (MTM). The sarcoma was judged grade 2 and IIIb stage, respectively according to FNCLCC and AJCC classifications. Surgery, as a first-line treatment option, was judged hazardous and difficult due to the anatomical relations of the tumor. Neoadjuvant chemotherapy, followed by a large resection of the mass and possible resort to radiotherapy as a post-operative treatment option, was our final multidisciplinary decision.

Conclusion : Every retroperitoneal tumor isto be considered as suspicious of soft-tissue sarcoma. Definitive diagnosis of retroperitoneal neoplasms requires histological confirmation, using a radiologically-guided microbiopsy. The cornerstone of treatment I slarge or compartmental surgical resection, when feasible. Radio and chemotherapyare precious treatment options for retroperitoneal sarcomas. FNCLCC grading and AJCC staging of retroperitoneal sarcomas determine the need to first-line radio or chemotherapy. In adjuvant setting, their indication depends on the quality of surgical excision. As the risk of recurrence is significant, watchful follow-up of patients with treated sarcoma is required.

38. Bridging Adjuvant treatment gaps: Low and Intermediate Risk Endometrial Carcinoma Patients Care in Salah Azaiez Institute in Tunisia

Boudhina E¹, Yahiaoui S¹, Sahraoui G², Yousfi A¹, Mousli A¹, Ben Zid K¹, Ghorbel A¹, Zarraa S¹, Abidi R¹, Nasr C¹

1) Radiation therapy Department, Salah Azaiez Institute, Tunis-Tunisia

2) Pathology Department, Salah Azaiez Institute, Tunis-Tunisia

Background: The management of Low and intermediate risk (LR, LIR and HIR) endometrial carcinoma at SAI in Tunisia has undergone transformative changes with evolving international recommendations and the advent of the molecular era. The impact of these changes results in a dual challenge of undertreatment, elevating recurrence risk, and overtreatment, burdening patients with increased toxicities. Since we lack access to the molecular tumor profiling in our institution, this study aims to clarify the connection between adherence to international recommendations and clinical outcomes.

Methods: A comprehensive retrospective transversal analytic study conducted in SAI Radiation Oncology Department in Tunisia, from 2015 to 2020, including 180 patients diagnosed with LR, LIR and HIR endometrial carcinoma, with a minimum follow-up of 3 years. Eleven histopathological slides underwent re-examination to precisely assess the number of invaded vessels.

Results: The median age within the cohort was 60 years old [35-69]. Among patients, hypertension was observed in 50.6% (n=91) of cases, diabetes in 31.7% (n=57) of cases, and cardiopathy in 6.1% (n=11) of cases. The duration of hormonal exposure, averaged 37 years. The results of endometrial biopsies in the study revealed 58.3% (n=105) of endometrioid adenocarcinoma. All included patients underwent surgery as a first-line treatment. A total abdominal hysterectomy along with bilateral salpingo-oophorectomy was performed in 54 patients, additional lymph node dissection was performed in 104 patients and an additional colpectomy was carried out in 31 patients. The definitive histopathology results in our cohort showed a median tumor size of 35 mm [3-80], grade 2 tumor was observed in 51.1% (n=92) of cases, myometrial invasion < 50% was observed in 54,5% (n=97) of cases and it was absent in 2,8% (n=5) of cases, cervical invasion was identified in 45% (n=45) of cases, no LVSI was found in 87,8% (n=158) of cases, extensive LVSI was found in 8,3% (n=15) of cases and focal LVSI was noted in 3,9% (n=7) of cases and p53 mutation data was available for only 2 patients, and in both cases, it was not mutated. According to FIGO 2009 staging, patients' disease was classified in 38,4% (n=69) as IA, in 36.1% (n=65) as IB and in 25.5% (n=46) as stage II. As for adjuvant treatment, VBT alone was delivered in 50% (n=90) of patients, 44,4% (n=80) of patients received both VBT and pelvic EBRT, 5% (n=9) of patients did not receive any adjuvant treatment, while 0,6% (n=1) received pelvic EBRT alone. it was observed that 47,2% (n=85) of patients underwent treatment that aligned with the recommended guidelines, over-treatment was noted in 47,2% (n=54) of cases with a significant majority among the LR group, accounting for 63.5% (n=54) of overtreated patients. Suboptimal treatment was delivered for 5,6% (n=10) of patients within the HIR group. At a 3-year follow-up, our study showed that 71.1% (n=128) of the population, achieved disease control. In 4.4% of cases (n=8) there was LR relapse and in 1.7% of cases (n=3) metastatic disease was observed. Gastro-intestinal late toxicities were observed in 26.7% (n=48) of cases, genito-urinary late toxicities were observed in 28.3% (n=51) of cases and sexual-related late toxicities were observed in 12.8% (n=23) of cases. Regarding treatment conformity towards actual treatment guidelines, over-treatment was linked to 7.9 times higher risk of death (p-value<0.001, HR 7.9, 95% CI: 5-8.7), and it showed 6.6 times higher risk of recurrence (p-value=0.006, HR 6.6, 95% CI: 1.7-25.45). Under-treatment wasn't identified as a prognostic factor, but this lack of association may be attributed to the limited size of the under-treated population. Age, adjuvant treatment, EBRT delay, EBRT dose, and over-

treatment collectively contributed to toxicity installation (30% to 49.5%). Overall, over and conformally treated patients led to a higher number of GI, GU and sexually-related late toxicities, with p-values<0.05.

Conclusion: In Tunisia, the potential for personalized care in the molecular era is hampered by limited access to molecular profiling. Despite these challenges, we aspire to explore the integration of molecular classification in the future.

39. Does hypofractionation irradiation for breast cancer increase oesophagitis among elderly patients ?

Felfoul A¹, Tbessi S¹, Bettaieb O¹, Souissi M¹, Kanoun S¹, Bouzid N¹, Tebra S¹

The Department of Radiotherapy Oncology, Farhat Hached Hospital of Sousse, Tunisia

Introduction : The risk of developing any acute toxicity such as radiation induced oesophagitis remains an issue for any radiation oncologist especially when using hypofractionation regimen for elderly patients with breast cancer Due to its anatomical position. Hence the aim of ourwork is to establish the doses received by the oesophagus in hypofractionated adjuvant radiotherapy (RT) Radiation induced oesophagitis represents a dreadful acute toxicity in the treatment of locally advanced breast cancer especially among elderly.

Materials and methods : This is a retrospective study, which included the treatment plans of 26 patients older than 65 years treated, in the department of radiotherapy oncology of sousse, for breast cancer by loco-regional RT withhypofractionationregimen (40Gy in 15 fractions) over the period from september 2020 (the date we began the use of hypofractionation regimen conformational 3D RT, using monoisocentric techniques) to january 2022. We delineated the oesophagus according to the (radiation therapy oncology group) RTOG recommandations and we recorded the maximum dose (DMax) as well as the mean dose at its level.

Results : The mean age of our patients was 70 years [65-81 years]. Sixteen patients (61.5%) had left breast cancer. Twenty two patients (84.6%) underwent radical mastectomy and 4 patients (15.4%) had conservative surgery. A boost on the tumor bed or on the chest wall was indicated in 7 cases (26.9%) at a dose of 13.35 Gy, 5 fractions per week. All our patients were treated with the conformational 3D technique. Ipsilateral axillary region was included in 12 patients (46%). The mean median dose received by the oesophagus was 2 Gy [0.6 Gy-13Gy]. The mean of DMax was 21 Gy [2.6 Gy-41 Gy]. Only four patients received a dose more than 35 Gy to the oesophagus which presented odyphagia. Dmax was significantly correlated with axillary irradiation and left breast cancer irradiation (P=0.006 and 0.042 respectively).

Conclusion: Oesophagitis is an acute toxicity in breast cancer irradiation, even with the hypofractionation regimen, that may affect the treatment process because of the frail ground and the vulnerability of this category of patients especially in the case of a loco-regional irradiation of left breast cancer.