

Case Report

A pulmonary hernia against pressure regime: a residual cavity related complication following liver hydatid cyst surgery: Case Report

Mohamed Ali Mseddi^{1*}, Karim Sassi¹, Sarra Zairi², Rakia Siala¹, Rami Guizani¹, Chaima Yaacoubi¹, Bechir Zahaf¹, Mohamed Ben Slima¹

¹Department of General Surgery B. La Rabta Hospital - Tunis. Medical school of Tunis - University of Tunis El Manar, Tunisia

²Department of thoracic surgery. Abderrahmane Mami Hospital - Ariana. Medical school of Tunis - University of Tunis El Manar, Tunisia

Abstract

Echinococcosis raises a public health issue in many countries, although it is, in principle, preventable, treatable and eradicable. Surgery is the keystone of its treatment. Conservative procedures offer fewer per-operative complications but predisposes to post-operative complications. Herein we report an unprecedented complication of the residual cavity: an intra-abdominal transdiaphragmatic pulmonary hernia occurring 3 years after the index surgery. A 64-year-old woman with no relevant medical history, consulted for dull hepatalgia with no respiratory complains. Radio-imaging concluded to a pulmonary hernia into the residual cavity. Taking into consideration the well tolerated abdominal discomfort and the potentially risky surgery, she was scheduled for a close follow-up. To our best knowledge, this is the first publication of intra-abdominal pulmonary hernia. Normally, herniation follows the pressure gradient present between thoracic and abdominal cavities. The consequences can be dreadful because of the threat to the pulmonary parenchyma, from the reduction of its functional capacity to its necrosis. Operation will be restricted to cases of functional respiratory repercussions or important pulmonary contusion.

Keywords: pulmonary, hernia, hydatid, cyst, residual, cavity, surgery

Received: March 9, 2024; Accepted: March 26, 2024

1. Introduction

Echinococcosis is a complex disease. It continues to be a major public health problem in many countries, although it is, in principle, preventable, treatable and eradicable. This data is supported by a recent Tunisian survey stating that the annual incidence dropped slightly from 15 to 12,6 per 100 000 inhabitants in a time lapse of 30 years [1]; despite the implement of control programme against hydatid cyst. In Tatouine, considered the most hypo-endemic region in Tunisia, the prevalence of hydatidosis in livestock was 1.6% [2]. Surgery is the keystone of its treatment, to offer better longstanding results as 93,3% of cysts are fertile [3], thus suggesting its evolving pattern. Conservative procedures offer fewer per-operative complications but predisposes to post-operative complications. Herein we report an unprecedented complication of the residual cavity: intra-abdominal transdiaphragmatic pulmonary hernia.

2. Case report

A 64-year-old patient underwent surgery 3 years ago to remove a 10 cm segment VII type IV hepatic hydatid cyst

fistulized in the bile ducts (Fig.1). She had a partial open perikystectomy with cholecystectomy and drainage in contact with the residual cavity. Per-operatively, the cyst was symphyseal to the ipsilateral diaphragmatic dome.

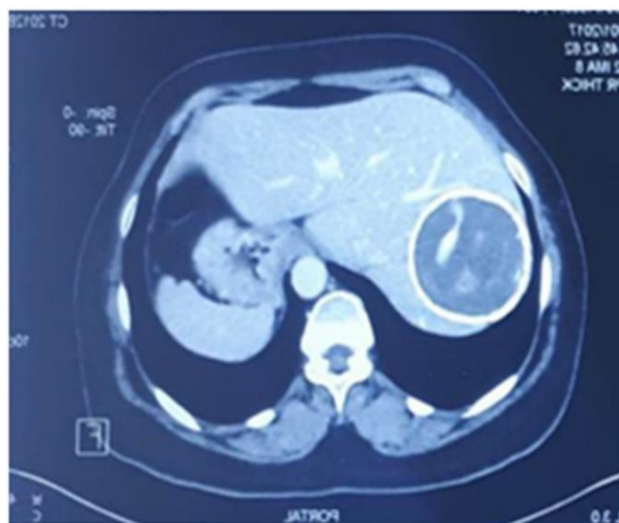


Fig.1. Former abdominal CT scan displaying the hydatid cyst of the liver.

*Correspondence: Dr Mohamed Ali Mseddi. Department of General Surgery B. La Rabta Hospital, University of Tunis El Manar, Tunisia. Email mseedibaka@yahoo.fr

Because of fear of diaphragmatic breach, the emerging part of the cyst was gently separated from the diaphragmatic membrane, which was hepatized. The postoperative course was favorable and she was discharged on 7th postoperative day. She reconsulted 1 year later with dull right upper quadrant pain without respiratory complaint. The physical examination was unremarkable except for a crackling sound projected on the hepatic area. Blood picture was within normal range. Abdominal CT-scan revealed herniation of the right lung base through a large diaphragmatic breach of 7 cm protruding into the residual cavity containing the antero and infero-basal segments of the right inferior lobe which are normally ventilated, peripheral calcification of old shell of the resected cyst (Fig.2).

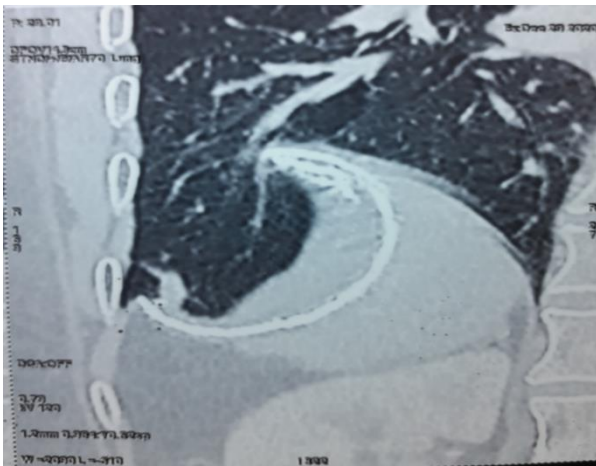


Fig.2. Frontal slice of the abdominal CT-scan illustrating the herniation of the inferior pulmonary lobe by trans-diaphragmatic path into the residual cavity.

Diaphragmatic MRI exhibited a residual cavity overlapping hepatic segments VII and VIII with calcified shell containing lung parenchyma and small fluid effusion, diaphragmatic defect overlooking the shell extending over 60 mm (Fig.3). Spirometry overruled obstructive pattern. Pulmonary CT angiography excluded pulmonary infarction. Upon completion of this assessment, surgery was postponed because of lack of severe complains and redo-surgery was deemed hazardous.

The patient was scheduled for bi-annual control. One year and a half later, the patient was doing well, tolerating her discomfort with no added symptoms. The patient agrees with the decision taken after having evaluated the risk-benefit balance, she is regularly followed-up in our department in order to watch out for any worsening.

3. Discussion

Hydatidosis is rampant in Tunisia [4]. It raises a public health issue. It represents an economic burden because it requires a heavy surgical intervention and/or a prolonged drug treatment. Bovines generally have infertile cysts, whereas infected sheep generally have fertile ones [5]. Thus, explaining its high incidence in Mediterranean basin, where sheep is the main source of red meat because they adapt better to the Mediterranean coastal steppes.

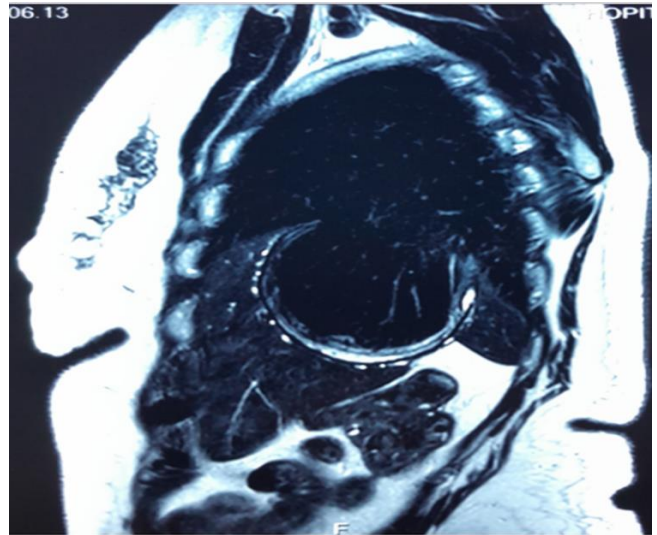


Fig.3. Diaphragmatic MRI examining the integrity of the phrenic membrane and revealing a residual cavity overlapping hepatic segments VII and VIII with calcified shell containing lung parenchyma and small fluid effusion, diaphragmatic defect overlooking the shell extending over 60 mm.

In spite of the advances in the management of hepatic hydatidosis, its surgery is fraught with serious complications. The procedures performed in the conservative method are prone to postoperative complications related to the residual cavity. In a recent large retrospective analysis [6], where 68.9% of 914 patients were approached conservatively, external biliary fistula (68.7%), bilioma (10%), superinfection of residual cavity (16%) have prevailed in troubled post-operative course. In this case, we report a complication that has not been reported before in the Lagrot procedure. Moreover, to our best knowledge, this is the first publication of intra-abdominal pulmonary hernia.

This event can be explained by the following sequence:

- 1) The hepatic hydatid cyst of the previous operation was in the process of breaking open in the thorax.
- 2) By the attrition inflicted by the mechanical abrasion between the emergent surface of the hydatid cyst and the phrenic dome at each respiratory movement as well as the corrosive effect of the intra-cystic bile, the phrenic layer became emaciated making it frail.
- 3) During the resection of the protruding dome and because of the cystophrenic symphysis, additional phrenic layers had to be removed, further worsening the phrenic parietal fragility.
- 4) In the postoperative period, the remanent pericyst symphysed again with the phrenic dome owing to negative intrapleural pressure which tends to aspirate the below viscera, and the shrinking of the liver in the perspective of the parenchymal remodeling attracted the ipsilateral inferior pulmonary lobe like a vacuum cup. This explains the herniation of the liver against the caudorostral pressure gradient. Normally, herniation follows the pressure gradient present between thoracic and abdominal cavities. The pressure gradient in between these cavities is normally in the range of 7–20 cm of H₂O [7].

The consequences can be dreadful because of the threat to the pulmonary parenchyma, from the reduction of its functional capacity to its necrosis.

The operative indication seems to us to be based on the consequences. The surgical revision would be hazardous because of the hepato-pulmonary symphysis. The operation will be restricted to cases of functional respiratory repercussions or important pulmonary contusion [8]. In order to evaluate a possible amputation of the lung parenchyma, a spirometry with a CT scan of the lung should be prescribed. We check for obstructive pattern of airflow limitation on spirometry [9].

Surgical approach should be via an abdominal access because of intra-abdominal adhesions. The hernia defect should be repaired with non-absorbable sutures [10]. An interposition of reinforcing mesh is mandatory in case of large diaphragmatic gap [11] or irreducible orifice by muscular retracting [12]. It is important to be conservative in dealing with pulmonary complications as they are in the majority reversible [13]. Our patient was proposed to be monitored in the absence of signs of severity.

Conclusions

The hydatid cyst of the liver represents a pathology with pleomorphic presentation and of delicate management because of possible complications arising. This paper reports an unusual and potentially serious complication: intra-abdominal trans-diaphragmatic pulmonary hernia into the residual cavity.

Consent of patient

Written informed consent was obtained from the patient for participation in this study.

Consent for publication

Written informed consent was obtained from the patient to publish this report in accordance with the journal's patient consent policy.

Funding

None.

Conflict of Interest Disclosures

The authors declare no competing interest.

Availability of data and materials

All data underlying the manuscript are available as part of the article.

Authors' contributions

The authors participated equally. The final version of manuscript was read and approved by all authors.

References

[1] Chahed M, Bellali H, Touinsi H, Cherif R, Ben Safta Z, Essoussi M, et al. L'incidence chirurgicale du kyste

hydatique en Tunisie Résultats de l'enquête 2001-2005 et tendance évolutive entre 1977-2005. *Arch Inst Pasteur Tunis*. 2010;87(1-2):43-52.

- [2] M'rad S, Chaâbane-Banaoues R, Ghrab M, Babba H, Oudni-M'rad M. Human and animal cystic echinococcosis in Tataouine governorate: hypoendemic area in a hyperendemic country, myth or reality?. *Parasites Vectors*. 2021;14(1):216. <https://doi.org/10.1186/s13071-021-04714-5>
- [3] Lahmar S, Rebaï W, Boufana BS, Craig PS, Ksantini R, Daghfous A, et al. Cystic echinococcosis in Tunisia: analysis of hydatid cysts that have been surgically removed from patients. *Ann Trop Med Parasitol*. 2009;103(7):593-604. <https://doi.org/10.1179/000349809X12502035776153>
- [4] Bellil S, Limaïem F, Bellil K, Chelly I, Mekni A, Haouet S, Kchir N, Zitouna M. Descriptive epidemiology of extrapulmonary hydatid cysts: a report of 265 tunisian cases. *Tunis Med*. 2009;87(2):123-6. <https://doi.org/10.1016/j.medmal.2009.03.002>
- [5] Daryani A, Sharif M, Amouei A, Nasrolahei M. Fertility and viability rates of hydatid cysts in slaughtered animals in the Mazandaran Province, Northern Iran. *Trop Anim Health Prod*. 2009;41(8):1701-5. <https://doi.org/10.1007/s11250-009-9368-x>
- [6] Farhat W, Rguez A, Mizouni A, Said MA, Damak N, Mabrouk MB, et al. Le kyste hydatique du foie: un traitement radical ou conservateur?. *J Visc Surg*. 2020;157(Suppl. 3):S167. <https://doi.org/10.1016/j.jchirv.2020.07.080>
- [7] Vempalli N, Konda S, Kaeley N, Bhardwaj B, Kumar S. Post-traumatic diaphragmatic hernia: Diagnostic dilemma in primary care. *J Family Med Prim Care*. 2020;9(5):2555. https://doi.org/10.4103/jfmpe.jfmpe_160_20
- [8] Aguir S, Boddart G, Weber G, Hornez E, Pons F. Hernie pulmonaire intercostale secondaire à un effort de toux. *Rev Pneumol Clin*. 2015;71(1):60-3. <https://doi.org/10.1016/j.pneumo.2014.11.005>
- [9] Shameem M, Saad T, Bhargava R, Ahmed Z, Pandey DK, Fatima N. Hernia of lung through the anterior chest wall. *Respir Med CME*. 2008;1(2):137-9. <https://doi.org/10.1016/j.rmedc.2008.03.002>
- [10] El-Yakub AI, Bello UM, Sheshe AA, Naaya HU. Delayed presentation of posttraumatic diaphragmatic hernia masquerading as recurrent acute asthmatic attack. *Clin Med Case Rep*. 2017;2017:1-3. <https://doi.org/10.1155/2017/5037619>
- [11] Giuffrida M, Perrone G, Abu-Zidan F, Agnoletti V, Ansaloni L, Baiocchi GL, et al. Management of complicated diaphragmatic hernia in the acute setting: a WSES position paper. *World J Emerg Surg*. 2023;18(1):43. <https://doi.org/10.1186/s13017-023-00510-x>
- [12] Schwartz A, Desolneux G, Desjardin M, Evrard S, Bechade D. Hernie diaphragmatique symptomatique à distance d'une ablathérapie pulmonaire par radiofréquence. *J Visc Surg*. 2013;150(2):177-8. <https://doi.org/10.1016/j.jchirv.2012.10.011>
- [13] Xanthakis DS, Katsaras E, Efthimiadis M, Papadakis G, Varouchakis G, Aligizakis C. Hydatid cyst of the liver with intrathoracic rupture. *Thorax*. 1981;36(7):497-501. <https://doi.org/10.1136/thx.36.7.497>

Cite this article as: Mseddi MA, Sassi K, Zairi S, Siala R, Guizani R, Yaacoubi C, Zahaf B, Ben Slima M. A pulmonary hernia against pressure regime: a residual cavity related complication following liver hydatid cyst surgery: Case Report. *Biomedicine Healthcare Res* 2024;3:12-4. <https://doi.org/10.71599/bhr.v3i1.116>